

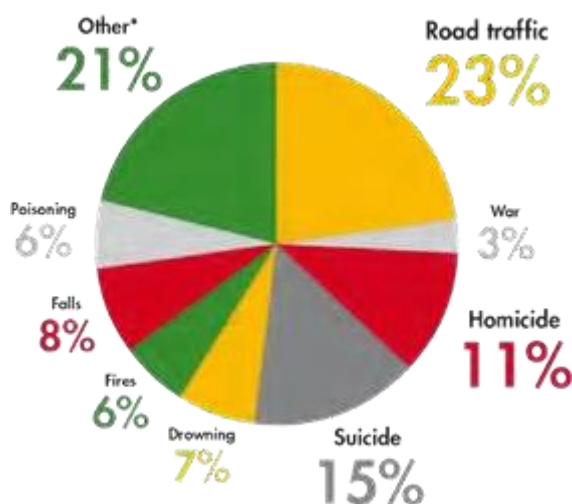
# Thoracic Trauma

State University of Medicine and Pharmacy  
“Nicolae Testemitanu”,

Malacinschi Tatiana, MD, PhD, university assistant

1. Primary survey
2. Resuscitation
3. Secondary survey
4. Diagnostic evaluation
5. Definitive care

**Introduction** According to the most current information from the World Health Organization (WHO) and the Centers for Disease Control (CDC), more than nine people die every minute from injuries or violence, and 5.8 million people of all ages and economic groups die every year from unintentional injuries and violence ( **FIGURE 1**). The burden of injury is even more significant, accounting for 18% of the world’s total diseases. Motor vehicle crashes (referred to as road traffic injuries) alone cause more than 1 million deaths annually and an estimated 20 million to 50 million significant injuries; they are the leading cause of death due to injury worldwide. Improvements in injury control efforts are having an impact in most developed countries, where trauma remains the leading cause of death in persons 1 through 44 years of age. Significantly, more than 90% of motor vehicle crashes occur in the developing world. Injury-related deaths are expected to rise dramatically by 2020, and deaths due to motor vehicle crashes are projected to increase by 80% from current rates in low- and middle-income countries.



**FIGURE 1** Distribution of global injury mortality by cause. “Other” category includes smothering, asphyxiation, choking, animal and venomous bites, hypothermia, and hyperthermia as well as natural disasters. Data from *Global Burden of Disease*, 2004. Reproduced with permission from *Injuries and Violence: The Facts*. Geneva: World Health Organization Department of Injuries and Violence Prevention; 2010.

Thoracic trauma is a significant cause of mortality; in fact, many patients with thoracic trauma die after reaching the hospital. However, many of these deaths can be prevented with prompt diagnosis and treatment. Less than 10% of blunt chest injuries and only 15% to 30% of penetrating chest injuries require operative intervention.

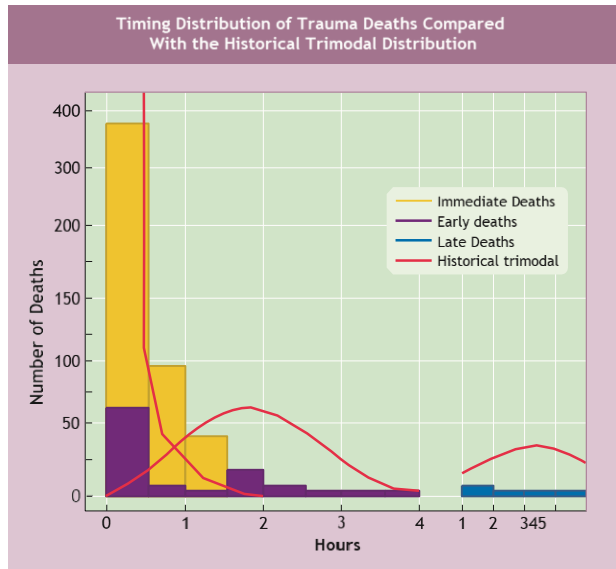


FIGURE 2 Timing distribution of trauma deaths compared with the historical trimodal distribution. The black line represents the historical trimodal distribution, and the bars represent 2010 study data.

The three peaks of occurrence are immediate, early, and late( FIGURE 2). Immediate deaths represent 50% and are caused by massive head injury, brain stem injury, and major cardiovascular injury. Early deaths occur within the first few hours and represent 30%. Major torso trauma, which accounts for most early deaths, is treatable in modern trauma centers. The concept of a "golden hour" following injury arises from consideration of this group. Late deaths represent 20% of all in-hospital deaths due to trauma. Organ failure and sepsis account for most of these after a prolonged period of critical illness.

The physiologic consequences of thoracic trauma are hypoxia, hypercarbia, and acidosis. Contusion, hematoma, and alveolar collapse, or changes in intrathoracic pressure relationships (e.g., tension pneumothorax and open pneumothorax) cause hypoxia and lead to metabolic acidosis. Hypercarbia causes respiratory acidosis and most often follows inadequate ventilation caused by changes in intrathoracic pressure relationships and depressed level of consciousness.

**Consider that patient factors may affect parameters:**

- Young, healthy patients have increased cardiac reserve and may be able to tolerate greater hemorrhage but may deteriorate rapidly once compensatory mechanism are exhausted.
- Athletes, who may have resting heart rates in the 40s and 50s, may be relatively tachycardic with heart rates in the 80s and 90s.
- The elderly may not respond to hemorrhage with tachycardia because of heart disease or medications (typically chronotropes, such as beta-blockers, digoxin).
- Pregnant, especially in the third trimester, may have a more pronounced response to minor hemorrhage, given poor venous return from a gravid uterus, and also have a significantly increased circulating volume.
- Those with heart transplants will not respond sufficiently to hemorrhage or shock.

## PRIMARY AND SECONDARY SURVEY

As in all trauma patients, the primary survey of patients with thoracic injuries begins with the airway, followed by breathing and then circulation. **Major problems should be corrected as they are identified.** As in all trauma patients, the primary survey of patients with thoracic injuries begins with the airway, followed by breathing and then circulation. **Major problems should be corrected as they are identified.** Assessment of thoracic trauma requires the identification of immediately life-threatening injuries on primary survey, and delayed life threats on secondary survey.

### Immediately life-threatening thoracic injuries

#### Airway Obstruction

#### Tracheobronchial Tree Injury

#### Tension Pneumothorax

#### Open Pneumothorax

#### Massive Hemothorax Massive Hemothorax

#### Cardiac Tamponade

#### Traumatic Circulatory Arrest

#### Airway problems

It is critical to recognize and address major injuries affecting the airway during the primary survey.

#### Airway Obstruction

Airway obstruction results from swelling, bleeding, or vomitus that is aspirated into the airway, interfering with gas exchange. Several injury mechanisms can produce this type of problem. Laryngeal injury can accompany major thoracic trauma or result from a direct blow to the neck or a shoulder restraint that is misplaced across the neck. Posterior dislocation of the clavicular head occasionally leads to airway obstruction. Alternatively, penetrating trauma involving the neck or chest can result in injury and bleeding, which produces obstruction. Although the clinical presentation is occasionally subtle, acute airway obstruction from laryngeal trauma is a life-threatening injury. During the primary survey, look for evidence of air hunger, such as intercostal and supraclavicular muscle retractions. Inspect the oropharynx for foreign body obstruction. Listen for air movement at the patient's nose, mouth, and lung fields. Listen for evidence of partial upper airway obstruction (stridor) or a marked change in the expected voice quality in patients who are able to speak. Feel for crepitus over the anterior neck.

#### Recognition

- External neck deformity or hematoma, crepitus from laryngeal fracture, surgical emphysema, hoarse voice or gurgling
- Complete airway obstruction — silent chest, paradoxical chest movements
- Partial airway obstruction — stridor, respiratory distress
- Cyanosis

#### Management

- High flow oxygen 15 L/min via non-rebreather mask
- Use airway maneuvers and adjuncts to attempt to achieve airway patency (jaw-thrust, suction, oropharyngeal airway) and rapidly proceed to definitive airway if airway disruption confirmed
- Surgical airway may be required as endotracheal intubation with direct laryngoscopy may not be possible due to distorted anatomy

- If a disrupted airway is visible through an open neck wound attempt to secure the distal trachea with forceps (retraction) and intubate through the wound (consider using a bougie)
- Will need bronchoscopy / thoracotomy

Patients with airway obstruction may be treated with clearance of the blood or vomitus from the airway by suctioning. This maneuver is frequently only temporizing, and placement of a definitive airway is necessary. Palpate for a defect in the region of the sternoclavicular joint. Reduce a posterior dislocation or fracture of the clavicle by extending the patient's shoulders or grasping the clavicle with a penetrating towel clamp, which may alleviate the obstruction. The reduction is typically stable when the patient remains in the supine position.

### **Tracheobronchial Tree Injury**

Injury to the trachea or a major bronchus is an unusual but potentially fatal condition. The majority of tracheobronchial tree injuries occur within 1 inch (2.54 cm) of the carina. These injuries can be severe, and the majority of patients die at the scene. Those who reach the hospital alive have a high mortality rate from associated injuries, inadequate airway, or development of a tension pneumothorax or tension pneumopericardium.

Rapid deceleration following blunt trauma produces injury where a point of attachment meets an area of mobility. Blast injuries commonly produce severe injury at air-fluid interfaces.

Penetrating trauma produces injury through direct laceration, tearing, or transfer of kinetic injury with cavitation. Intubation can potentially cause or worsen an injury to the trachea or proximal bronchi.

Patients typically present with hemoptysis, cervical subcutaneous emphysema, tension pneumothorax, and/or cyanosis. Incomplete expansion of the lung and continued large air leak after placement of a chest tube suggests a tracheobronchial injury, and placement of more than one chest tube may be necessary to overcome the significant air leak. Bronchoscopy confirms the diagnosis. If tracheobronchial injury is suspected, obtain immediate surgical consultation.

- Tracheobronchial injury usually occurs close to the carina, and is associated with severe blunt trauma

#### **Recognition**

Hemoptysis, cough and respiratory distress

- Subcutaneous emphysema
- Pneumothorax with persistent air leak after correct placement of an intercostal catheter (continues to bubble vigorously with little resolution of pneumothorax)

#### **Management**

- High flow oxygen 15 L/min via non-rebreather mask
- Multiple intercostal catheters may be required
  - Urgent bronchoscopy and operative intervention

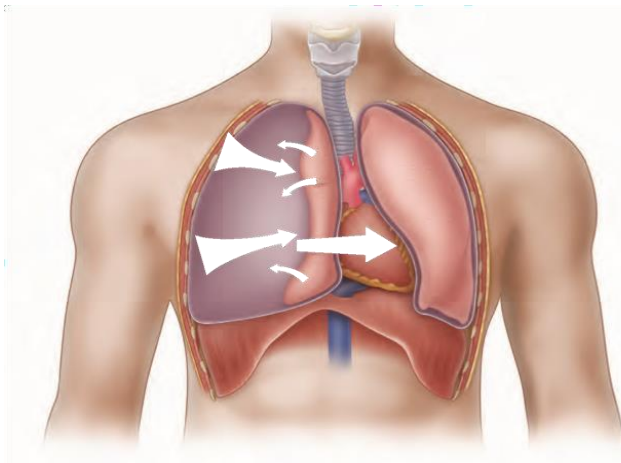
Immediate treatment may require placement of a definitive airway. Intubation of patients with tracheobronchial injuries is frequently difficult because of anatomic distortion from paratracheal hematoma, associated oropharyngeal injuries, and/or the tracheobronchial injury itself.

Advanced airway skills, such as fiber-optically assisted endotracheal tube placement, may be required. For such patients, immediate operative intervention is indicated. In more stable patients, operative treatment of tracheobronchial injuries may be delayed until the acute inflammation and edema resolve.

**Breathing problems** Completely expose the patient's chest and neck to allow for assessment of neck veins and breathing. This may require temporarily releasing the front of the cervical collar; in this case, actively restrict cervical motion by holding the patient's head while the collar is loosened. Look at the chest wall to assess movement and determine whether it is equal. Assess the adequacy of respirations. Listen to the chest to evaluate for equal breath sounds and identify any extra sounds that may indicate effusion or contusion. Palpate to determine if there are areas of tenderness, crepitus, or defects. Significant, yet often subtle, signs of chest injury and/or hypoxia include increased respiratory rate and changes in the patient's breathing pattern, which are often manifested by progressively shallow respirations. Recall that cyanosis is a late sign of hypoxia in trauma patients and can be difficult to perceive in darkly pigmented skin; its absence does not necessarily indicate adequate tissue oxygenation or an adequate airway. Tension pneumothorax, open pneumothorax (sucking chest wound), and massive hemothorax are the major thoracic injuries that affect breathing. It is imperative for clinicians to recognize and manage these injuries during the primary survey

### Tension Pneumothorax

Tension pneumothorax develops when a "one-way valve" air leak occurs from the lung or through the chest wall ( **FIGURE 3**). Air is forced into the pleural space with no means of escape, eventually collapsing the affected lung. The mediastinum is displaced to the opposite side, decreasing venous return and compressing the opposite lung. Shock (often classified as obstructive shock) results from marked decrease in venous return, causing a reduction in cardiac output.



**FIGURE 3** Tension Pneumothorax. A "one-way valve" air leak occurs from the lung or through the chest wall, and air is forced into the thoracic cavity, eventually collapsing the affected lung.

The most common cause of tension pneumothorax is mechanical positive-pressure ventilation in patients with visceral pleural injury. Tension pneumothorax also can complicate a simple pneumothorax following penetrating or blunt chest trauma in which a parenchymal lung injury fails to seal, or after attempted subclavian or internal jugular venous catheter insertion. Occasionally, traumatic defects in the chest wall cause a tension pneumothorax when occlusive dressings are secured on four sides or the defect itself constitutes a flap-valve mechanism. Rarely, tension pneumothorax occurs from markedly displaced thoracic spine fractures. Tension

pneumothorax is a clinical diagnosis reflecting air under pressure in the affected pleural space. Do not delay treatment to obtain radiologic confirmation.

Patients who are spontaneously breathing often manifest extreme tachypnea and air hunger, whereas patients who are mechanically ventilated manifest hemodynamic collapse. Tension pneumothorax is characterized by some or all of the following signs and symptoms:

- Chest pain
  - Air hunger
  - Tachypnea
  - Respiratory distress
  - Tachycardia
  - Hypotension
  - Tracheal deviation away from the side of the injury
  - Unilateral absence of breath sounds
  - Elevated hemithorax without respiratory movement
  - Neck vein distention
  - Cyanosis (late manifestation)
- Simple pneumothorax converts to a tension pneumothorax if the lung defect acts as a one way valve, which allows ongoing air leak into pleural space without letting it leak back out
  - Tension pneumothorax can be rapidly fatal as intra-thoracic pressure rises cause decreased venous return and kinking of great vessels resulting in obstructive shock
  - Have a high index of suspicion in any tachycardic and hypotensive patient — clinical features may not be obvious

A hyperresonant note on percussion, deviated trachea, distended neck veins, and absent breath sounds are signs of tension pneumothorax. Arterial saturation should be assessed using a pulse oximeter and will be decreased when tension pneumothorax is present. When ultrasound is available, tension pneumothorax can be diagnosed using an extended FAST (eFAST) examination.

Tension pneumothorax requires immediate decompression and may be managed initially by rapidly inserting a large over-the-needle catheter into the pleural space. Due to the variable thickness of the chest wall, kinking of the catheter, and other technical or anatomic complications, needle decompression may not be successful. In this case, finger thoracostomy is an alternative approach

#### Management

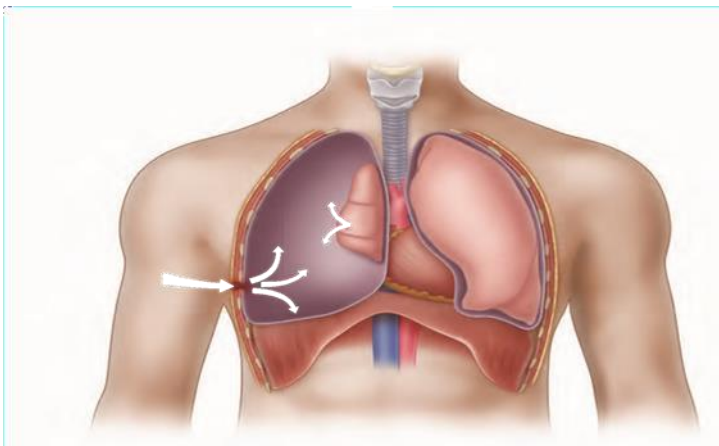
- High flow oxygen to maintain SpO<sub>2</sub> target (e.g. 15L/min via non-rebreather mask)
- Immediate needle thoracocentesis or finger thoracostomy ('decompression').
  - Proceed to formal intercostal catheter after needle decompression

Chest wall thickness influences the likelihood of success with needle decompression. Recent evidence supports placing the large, over-the-needle catheter at the fifth interspace, slightly anterior to the midaxillary line. However, even with an over-the-needle catheter of the appropriate size, the maneuver will not always be successful.

Successful needle decompression converts tension pneumothorax to a simple pneumothorax. However, there is a possibility of subsequent pneumothorax as a result of the maneuver, so

continual reassessment of the patient is necessary. Tube thoracostomy is mandatory after needle or finger decompression of the chest.

**Open Pneumothorax** Large injuries to the chest wall that remain open can result in an open pneumothorax, also known as a sucking chest wound (**FIGURE 4**). Equilibration between intrathoracic pressure and atmospheric pressure is immediate. Because air tends to follow the path of least resistance, when the opening in the chest wall is approximately two-thirds the diameter of the trachea or greater, air passes preferentially through the chest wall defect with each inspiration. Effective ventilation is thereby impaired, leading to hypoxia and hypercarbia. Open pneumothorax is commonly found and treated at the scene by prehospital personnel. The clinical signs and symptoms are pain, difficulty breathing, tachypnea, decreased breath sounds on the affected side, and noisy movement of air through the chest wall injury.



**FIGURE 4.** Open Pneumothorax.  
Large defects of the chest wall.

For initial management of an open pneumothorax, promptly close the defect with a sterile dressing large enough to overlap the wound's edges. Any occlusive dressing (e.g. plastic wrap or petrolatum gauze) may be used as temporary measure to enable rapid assessment to continue. Tape it securely on *only* three sides to provide a flutter-valve effect( **FIGURE 5**) .As the patient breathes in, the dressing occludes the wound, preventing air from entering. During exhalation, the open end of the dressing allows air to escape from the pleural space. Taping all four edges of the dressing can cause air to accumulate in the thoracic cavity, resulting in a tension pneumothorax unless a chest tube is in place. Place a chest tube remote from the wound as soon as possible. Subsequent definitive surgical closure of the wound is frequently required.

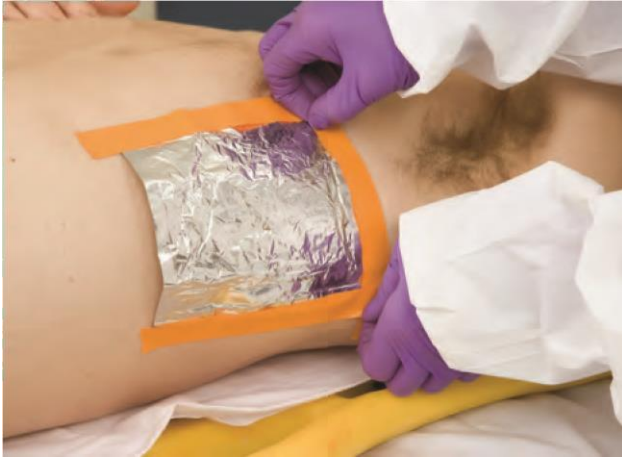- Open pneumothorax is essentially a 'sucking chest wound'
- It is thought that once a chest wound is  $>2/3$ ds the diameter of the trachea, air will enter wound preferentially

#### Recognition

- Open wound on chest wall
- Anxiety and agitation
- Respiratory distress
- Tachycardia
- Decreased chest movement ipsilaterally
- Hyper-resonance ipsilaterally
- Decreased breath sounds ipsilaterally
- Bedside ultrasound can rapidly confirm pneumothorax

#### Management

- High flow oxygen to maintain SpO2 target (e.g. 15L/min via non-rebreather mask)
- Cover with occlusive 3-sided dressing to form a 'flutter valve' that allows the egress of air through the wound but prevents 'sucking in'.
- Place formal catheter in separate intercostal space
  - Will need formal exploration prior to closing



**FIGURE 5** Dressing for Treatment of Open Pneumothorax. Promptly close the defect with a sterile occlusive dressing that is large enough to overlap the wound's edges. Tape it securely on three sides to provide a flutter-valve effect.

**Circulation problems** Major thoracic injuries that affect circulation and should be recognized and addressed during the primary survey are massive hemothorax, cardiac tamponade, and traumatic circulatory arrest.

Pulseless electrical activity (PEA) is manifested by an electrocardiogram (ECG) that shows a rhythm while the patient has no identifiable pulse. This dysrhythmia can be present with cardiac tamponade, tension pneumothorax, or profound hypovolemia. Severe blunt injury can result in blunt rupture of the atria or the ventricles, and the only manifestation may be PEA arrest. Other causes of PEA arrest include hypovolemia, hypoxia, hydrogen ion (acidosis), hypokalemia/hyperkalemia, hypoglycemia, hypothermia, toxins, cardiac tamponade, tension pneumothorax, and thrombosis (coronary or pulmonary). Inspect the skin for mottling, cyanosis, and pallor. Neck veins should be assessed for distention, although they may not be distended in patients with concomitant hypovolemia. Listen for the regularity and quality of the heartbeat. Assess central pulse for quality, rate, and regularity. In patients with hypovolemia, the distal pulses may be absent because of volume depletion. Palpate the skin to assess its temperature and determine whether it is dry or sweaty.

Measure blood pressure and pulse pressure, and monitor the patient with electrocardiography and pulse oximetry. Patients with blunt chest injury are at risk for myocardial dysfunction, which is increased by the presence of hypoxia and acidosis. Dysrhythmias should be managed according to standard protocols.

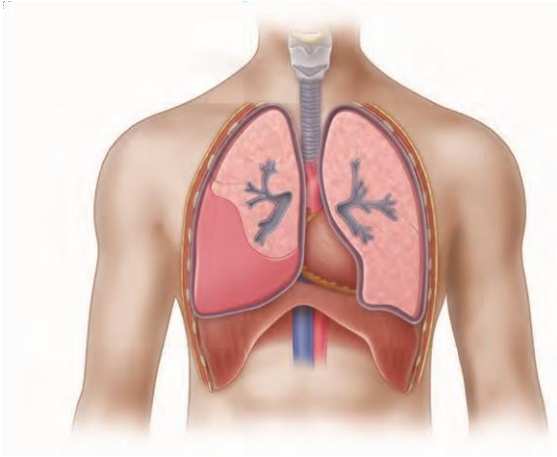
#### **Massive Hemothorax Massive Hemothorax**

Massive hemothorax results from the rapid accumulation of more than 1500 mL of blood or onethird or more of the patient's blood volume in the chest cavity (**FIGURE 6**). It is most commonly caused by a penetrating wound that disrupts the systemic or hilar vessels, although massive hemothorax can also result from blunt trauma.

In patients with massive hemothorax, the neck veins may be flat due to severe hypovolemia, or they may be distended if there is an associated tension pneumothorax. Rarely will the mechanical



effects of massive intrathoracic blood shift the mediastinum enough to cause distended neck veins. A massive hemothorax is suggested when shock is associated with the absence of breath sounds or dullness to percussion on one side of the chest.



**FIGURE 6. Massive Hemothorax.**

This condition results from the rapid accumulation of more than 1500 mL of blood or one-third or more of the patient's blood volume in the chest cavity.

- Massive hemothorax can result from either blunt or penetrating trauma
- The source of bleeding can be from the lungs, major vessels, intercostal vessels or even the heart

Massive hemothorax is defined by the need for thoracotomy — the indications are:

- Blood loss > 1,500 mL or 1/3rd of blood volume
- Blood loss >200 mL/h (3 mL/kg/h) for 2-4 hours

Recognition

. Anxiety and agitation

- Hemorrhagic shock — pallor, tachycardia, hypotension, cool peripheries
- External evidence of thoracic injury
- Decreased chest movement ipsilaterally
- Ipsilateral dullness
- Decreased breath sounds ipsilaterally
- Persistent blood loss following intercostal catheter insertion
- Bedside ultrasound can rapidly confirm the presence of significant pleural fluid — to see on erect chest requires 250mL of blood

Management

- High flow oxygen to maintain SpO<sub>2</sub> target (e.g. 15L/min via non-rebreather mask)
- Treat with rapid restoration of blood volume combined with concurrent drainage of thorax
- Immediate intercostal catheter insertion (re-expanding lung may tamponade the bleeding vessels)
- Hemostatic resuscitation — activate massive transfusion protocol, use of an autotransfuser is ideal
- Thoracotomy
- If develops from blunt chest trauma may be able to consider embolisation

Massive hemothorax is initially managed by simultaneously restoring blood volume and decompressing the chest cavity. Establish large caliber intravenous lines, infuse crystalloid, and begin transfusion of uncrossmatched or type-specific blood as soon as possible. When appropriate, blood from the chest tube can be collected in a device suitable for autotransfusion.

A single chest tube (28-32 French) is inserted, usually at the fifth intercostal space, just anterior to the midaxillary line, and rapid restoration of volume continues as decompression of the chest cavity is completed. The immediate return of 1500 mL or more of blood generally indicates the need for urgent thoracotomy. Patients who have an initial output of less than 1500 mL of fluid, but continue to bleed, may also require thoracotomy. This decision is based on the rate of continuing blood loss (200 mL/hr for 2 to 4 hours), as well as the patient's physiologic status and whether the chest is completely evacuated of blood. Again, the persistent need for blood transfusion is an indication for thoracotomy. During patient resuscitation, the volume of blood initially drained from the chest tube and the rate of continuing blood loss must be factored into the resuscitation required. Color of the blood (indicating an arterial or venous source) is a poor indicator of the necessity for thoracotomy.

Penetrating anterior chest wounds medial to the nipple line and posterior wounds medial to the scapula (the mediastinal "box") should alert the practitioner to the possible need for thoracotomy because of potential damage to the great vessels, hilar structures, and the heart, with the associated potential for cardiac tamponade. **Do not perform thoracotomy unless a surgeon, qualified by training and experience, is present.**

### **Cardiac Tamponade**

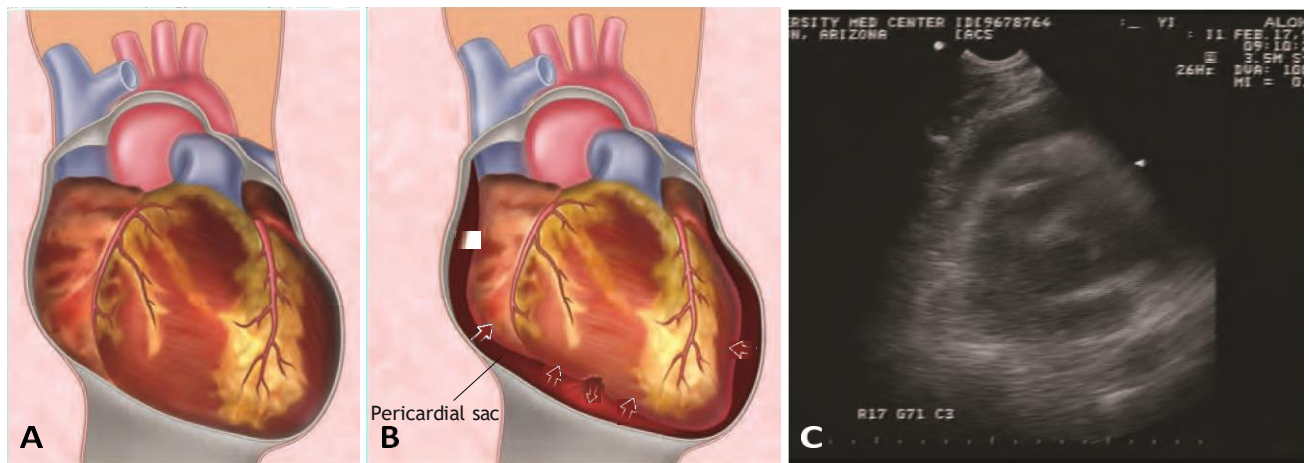
Cardiac tamponade is compression of the heart by an accumulation of fluid in the pericardial sac. This results in decreased cardiac output due to decreased inflow to the heart. The human pericardial sac is a fixed fibrous structure, and a relatively small amount of blood can restrict cardiac activity and interfere with cardiac filling. Cardiac tamponade most commonly results from penetrating injuries, although blunt injury also can cause the pericardium to fill with blood from the heart, great vessels, or epicardial vessels ( **FIGURE 7**).

Cardiac tamponade can develop slowly, allowing for a less urgent evaluation, or rapidly, requiring rapid diagnosis and treatment. The classic clinical triad of muffled heart sounds, hypotension, and distended veins is not uniformly present with cardiac tamponade. Muffled heart tones are difficult to assess in the noisy resuscitation room, and distended neck veins may be absent due to hypovolemia. Kussmaul's sign (i.e., a rise in venous pressure with inspiration when breathing spontaneously) is a true paradoxical venous pressure abnormality that is associated with tamponade. PEA is suggestive of cardiac tamponade but can have other causes, as explained earlier.

Tension pneumothorax, particularly on the left side, can mimic cardiac tamponade. Because of the similarity in their signs, tension pneumothorax can initially be confused with cardiac tamponade. The presence of hyperresonance on percussion indicates tension pneumothorax, whereas the presence of bilateral breath sounds indicates cardiac tamponade.

Focused assessment with sonography for trauma (FAST) is a rapid and accurate method of imaging the heart and pericardium that can effectively identify cardiac tamponade.

FAST is 90–95% accurate in identifying the presence of pericardial fluid for the experienced operator. Remember that tamponade can develop at any time during the resuscitation phase, and repeat FAST exams may be necessary. Providers experienced in ultrasonography may also be able to assess myocardial dysfunction and ventricular filling.



**FIGURE 7 Cardiac Tamponade.** **A.** Normal heart. **B.** Cardiac tamponade can result from penetrating or blunt injuries that cause the pericardium to fill with blood from the heart, great vessels, or pericardial vessels. **C.** Ultrasound image showing cardiac tamponade.

Additional methods of diagnosing cardiac tamponade include echocardiography and/or pericardial window, which may be particularly useful when FAST is unavailable or equivocal.

- Pericardial tamponade is more common in penetrating thoracic trauma than blunt trauma
- As little as 75 mL of blood accumulating in the pericardial space acutely can impair cardiac filling, resulting in tamponade and obstructive shock

#### Recognition

- Anxiety and agitation
- Obstructive shock — tachycardia, hypotension, cool peripheries
- Beck's triad: muffled heart sounds, hypotension and distended neck veins — not especially in a noisy trauma bay!
- Pulsus paradoxus (drop in systolic blood pressure >10 mmHg on inspiration)
- Very hard to differentiate clinically from tension pneumothorax and needs to be actively sought
- Mostly diagnosed following identification of a pericardial effusion on bedside ultrasound as part of the FAST exam leading to formal echocardiography

#### Management

- High flow oxygen to maintain SpO<sub>2</sub> target (e.g. 15L/min via non-rebreather mask)
- May transiently respond to fluid challenge
- Needle pericardiocentesis, preferably ultrasound guided, may be lifesaving may be life-saving but may fail due to clotted blood
- Pericardotomy is definitive treatment
- Emergency thoracotomy may be necessary in the event of cardiac arrest

#### Secondary survey

When pericardial fluid or tamponade is diagnosed, emergency thoracotomy or sternotomy should be performed by a qualified surgeon as soon as possible. Administration of intravenous fluid will raise the patient's venous pressure and improve cardiac output transiently while preparations are made for surgery. If surgical intervention is not possible, pericardiocentesis can be therapeutic, but it does not constitute definitive treatment for cardiac tamponade. When subxiphoid pericardiocentesis is used as a temporizing maneuver, the use of a large, over-the-needle catheter or the Seldinger technique for insertion of a flexible catheter is ideal, but the urgent priority is to aspirate blood from the pericardial sac. Because complications are common with blind insertion techniques, pericardiocentesis should represent a lifesaving measure of last resort in a setting where no qualified surgeon is available to perform a thoracotomy or sternotomy.

Ultrasound guidance can facilitate accurate insertion of the large, over-the-needle catheter into the pericardial space.

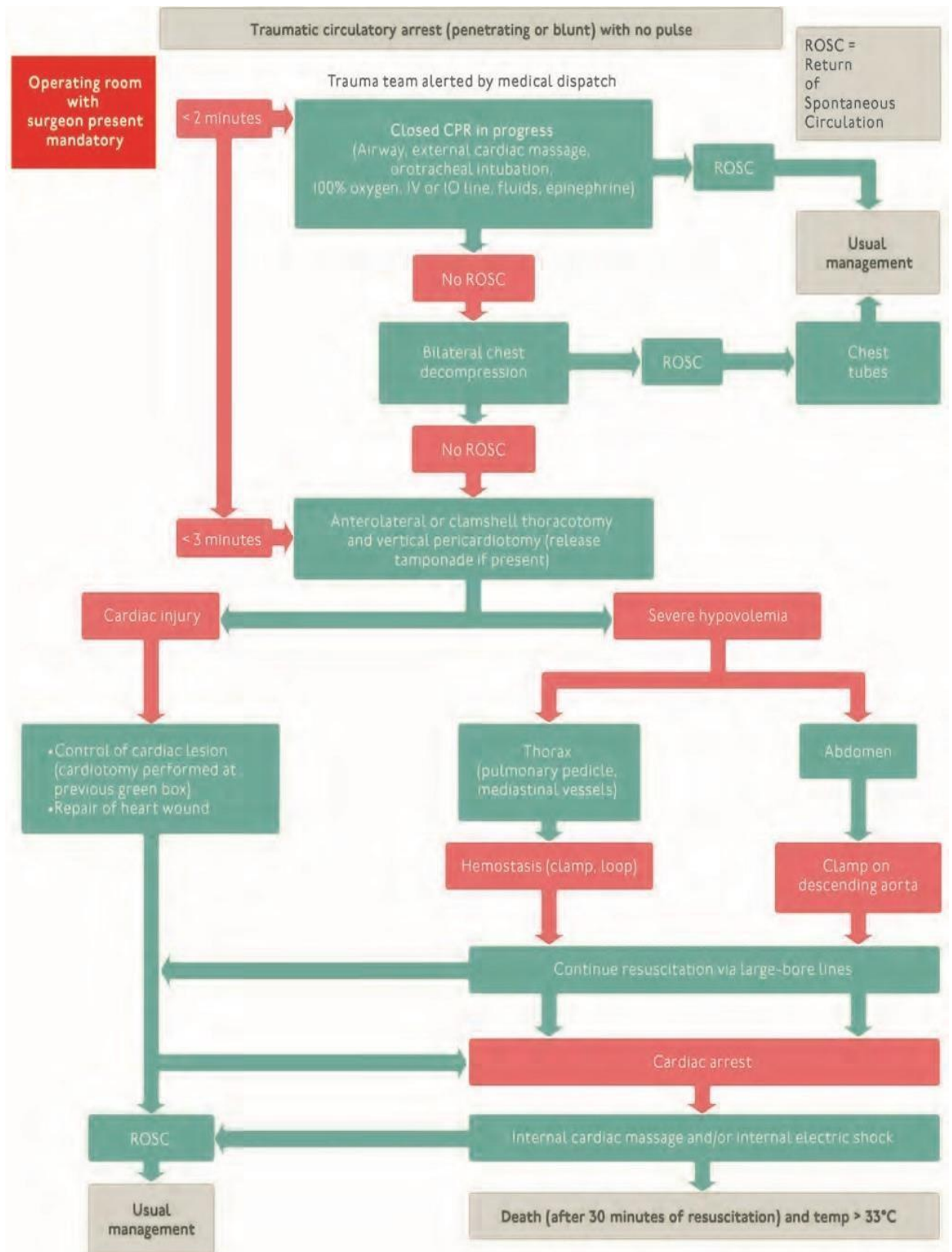
### **Traumatic Circulatory Arrest**

Trauma patients who are unconscious and have no pulse, including PEA (as observed in extreme hypovolemia), ventricular fibrillation, and asystole (true cardiac arrest) are considered to be in circulatory arrest. Causes of traumatic circulatory arrest include severe hypoxia, tension pneumothorax, profound hypovolemia, cardiac tamponade, cardiac herniation, and severe myocardial contusion. An important consideration is that a cardiac event may have preceded the traumatic event.

Circulatory arrest is diagnosed according to clinical findings (unconscious and no pulse) and requires immediate action. Every second counts, and there should be no delay for ECG monitoring or echocardiography. Recent evidence shows that some patients in traumatic circulatory arrest can survive (1.9%) if closed cardiopulmonary resuscitation (CPR) and appropriate resuscitation are performed. In centers proficient with resuscitative thoracotomy, 10% survival and higher has been reported with circulatory arrest following penetrating and blunt trauma.

Start closed CPR simultaneously with ABC management. Secure a definitive airway with orotracheal intubation (without rapid sequence induction). Administer mechanical ventilation with 100% oxygen. To alleviate a potential tension pneumothorax, perform bilateral finger or tube thoracostomies. No local anesthesia is necessary, as the patient is unconscious. Continuously monitor ECG and oxygen saturation, and begin rapid fluid resuscitation through large-bore IV lines or intraosseous needles. Administer epinephrine (1 mg) and, if ventricular fibrillation is present, treat it according to Advanced Cardiac Life Support (ACLS) protocols.

According to local policy and the availability of a surgical team skilled in repair of such injuries, a resuscitative thoracotomy may be required if there is no return of spontaneous circulation (ROSC). If no surgeon is available to perform the thoracotomy and cardiac tamponade has been diagnosed or is highly suspected, a decompressive needle pericardiocentesis may be performed, preferably under ultrasound guidance. **FIGURE 8** presents an algorithm for management of traumatic circulatory arrest.



**FIGURE 8 Algorithm for management of traumatic circulatory arrest.** ECM = external cardiac massage; OTI = orotracheal intubation; IVL = intravenous line; IOL = intraosseous line.

**Secondary survey** The secondary survey of patients with thoracic trauma involves further, in-depth physical examination, ongoing ECG and pulse oximetry monitoring, arterial blood gas (ABG) measurements, upright chest x-ray in patients without suspected spinal column instability, and chest computed tomography (CT) scan in selected patients with suspected aortic or spinal injury. In addition to lung expansion and the presence of fluid, the chest film should be reviewed for widening of the mediastinum, a shift of the midline, and loss of anatomic detail. Multiple rib fractures and fractures of the first or second rib(s) suggest that a significant force was delivered to the chest and underlying tissues. Extended FAST (eFAST) has been used to detect both pneumothoraces and hemothoraces. However, other potentially life-threatening injuries are not well visualized on ultrasound, making the chest radiograph a necessary part of any evaluation after traumatic injury

### **Potentially Life-threatening injuries**

Unlike immediately life-threatening conditions that are recognized during the primary survey, other potentially lethal injuries are often not obvious on initial physical examination. Diagnosis requires a high index of suspicion and appropriate use of adjunctive studies. If overlooked, these injuries can lead to increased complications or death.

The following eight potentially lethal injuries should be identified and managed during the secondary survey:

- Simple pneumothorax
- Hemothorax
- Flail chest
- Pulmonary contusion
- Blunt cardiac injury
- Traumatic aortic disruption
- Traumatic diaphragmatic injury
- Blunt esophageal rupture

### **Simple Pneumothorax**

Pneumothorax results from air entering the potential space between the visceral and parietal pleura

The thorax is typically completely filled by the lungs, which are held to the chest wall by surface tension between the pleural surfaces. Air in the pleural space disrupts the cohesive forces between the visceral and parietal pleura, allowing the lung to collapse. A ventilation-perfusion defect occurs because the blood that perfuses the nonventilated area is not oxygenated.

Both penetrating and nonpenetrating trauma can cause this injury. Lung laceration with air leakage is the most common cause of pneumothorax from blunt trauma.

Perform a comprehensive physical examination of the chest, including inspection for bruising, lacerations, and contusions. Assess movement of the chest wall and assess and compare breath sounds bilaterally. When a pneumothorax is present, breath sounds are often decreased on the affected side. Percussion may demonstrate hyperresonance.

#### Recognition

- Evidence of thoracic trauma
- Hyper-resonance ipsilaterally
- decreased breath sounds ipsilaterally
- Bedside ultrasound can rapidly confirm pneumothorax
- CT chest may diagnose small pneumothoraces not seen on CXR

#### Management

- High flow oxygen 15L/min via non-rebreather mask
- Small traumatic pneumothoraces may only require observation
- Significant simple pneumothoraces require intercostal catheter insertion, especially if the patient require intubation due to the risk of conversion to tension pneumothorax.

An upright expiratory chest x-ray aids in the diagnosis. Patients with blunt polytrauma are not candidates for this evaluation, although patients with penetrating chest trauma may be.

Any pneumothorax is best treated with a chest tube placed in the fifth intercostal space, just anterior to the midaxillary line. Observation and aspiration of a small, asymptomatic pneumothorax may be appropriate, but a qualified doctor should make this treatment decision. After inserting a chest tube and connecting it to an underwater seal apparatus with or without suction, a chest x-ray examination is done to confirm appropriate placement and reexpansion of the lung.

### **Hemothorax**

A hemothorax is a type of pleural effusion in which blood (<1500 mL) accumulates in the pleural cavity. The primary cause of hemothorax is laceration of the lung, great vessels, an intercostal vessel, or an internal mammary artery from penetrating or blunt trauma. Thoracic spine fractures may also be associated with a hemothorax. Bleeding is usually self-limited and does not require operative intervention.

Expose the chest and cervical areas, and observe the movement of the chest wall. Look for any penetrating chest wall injuries, including the posterior thorax. Assess and compare breath sounds in both hemithoraces. Typically, dullness to percussion is heard on the affected side. Obtain a chest x-ray with the patient in the supine position. A small amount of blood will be identified as a homogeneous opacity on the affected side.

An acute hemothorax that is large enough to appear on a chest x-ray may be treated with a 28-32 French chest tube. The chest tube evacuates blood, reduces the risk of a clotted hemothorax, and, allows for continuous monitoring of blood loss.

Evacuation of blood and fluid also enables clinicians to more completely assess the patient for potential diaphragmatic injury.

#### Recognition

- Respiratory distress, ipsilateral dullness
- On supine CXR films will appear as simply a veiling
- Bedside ultrasound can rapidly confirm fluid in the pleural space

#### Management

- High flow oxygen 15L/min via non-rebreather mask
- Intercostal catheter insertion (re-expansion of the ipsilateral lung may help tamponade bleeding vessels and ongoing blood loss can be monitored)

Greater than 1500 mL of blood obtained immediately through the chest tube indicates a massive hemothorax that may require operative intervention. Also, if drainage of more than 200 mL/hr for 2 to 4 hours occurs, or if blood transfusion is required, the trauma team should consider operative exploration. The ultimate decision for operative intervention is based on the patient's hemodynamic status.

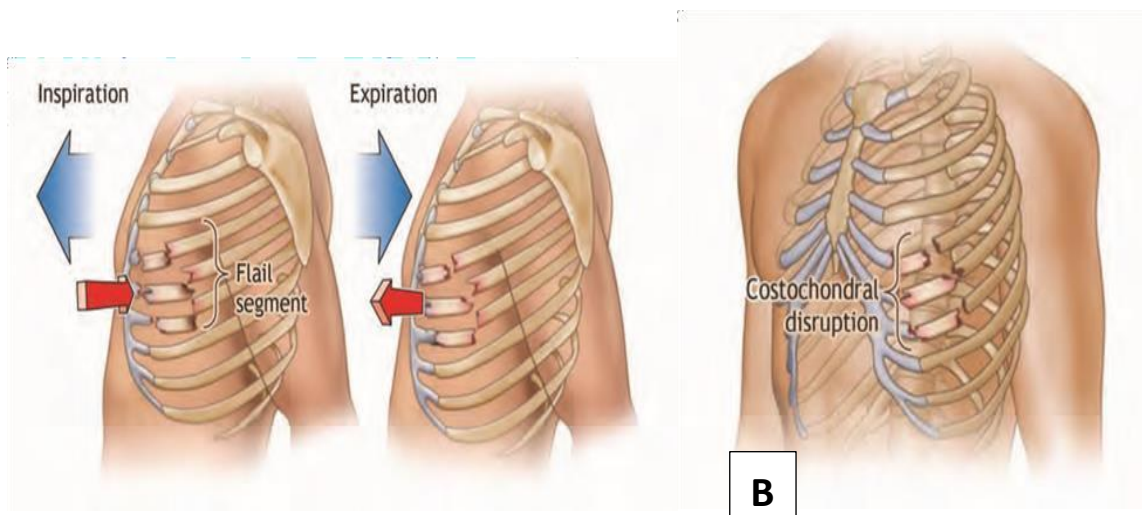
### Flail Chest and Pulmonary Contusion

A flail chest occurs when a segment of the chest wall does not have bony continuity with the rest of the thoracic cage. This condition usually results from trauma associated with multiple rib fractures (i.e., two or more adjacent ribs fractured in two or more places), although it can also occur when there is a costochondral separation of a single rib from the thorax ( **FIGURE 9**).

A pulmonary contusion is a bruise of the lung, caused by thoracic trauma. Blood and other fluids accumulate in the lung tissue, interfering with ventilation and potentially leading to hypoxia. Pulmonary contusion can occur without rib fractures or flail chest, particularly in young patients without completely ossified ribs. Children have far more compliant chest walls than adults and may suffer contusions and other internal chest injury without overlying rib fractures.

In adults, pulmonary contusion is most often encountered with concomitant rib fractures, and it is the most common potentially lethal chest injury. The resultant respiratory failure can be subtle, developing over time rather than occurring instantaneously. Limited ventilatory reserve may predispose older adult patients to early respiratory failure.

A flail segment may not be apparent by physical examination, particularly soon after injury. Decreased respiratory effort, combined with contusion and atelectasis, may limit movement of the chest wall. Thick chest wall musculature may also limit visualization of abnormal chest movement. If the injury results in significant underlying pulmonary contusion, serious hypoxia can result. Restricted chest wall movement associated with pain and underlying lung contusion can lead to respiratory failure.



**FIGURE 9 Flail Chest.** The presence of a flail chest segment results in disruption of normal chest wall movement. **A.** Flail chest from multiple rib fractures. **B.** Flail chest from costochondral separation.

Observation of abnormal respiratory motion and palpation of crepitus from rib or cartilage fractures can aid the diagnosis. A chest x-ray may suggest multiple rib fractures but may not show costochondral separation.



Initial treatment of flail chest and pulmonary contusion includes administration of humidified oxygen, adequate ventilation, and cautious fluid resuscitation. In the absence of systemic hypotension, the administration of crystalloid intravenous solutions should be carefully controlled to prevent volume overload, which can further compromise the patient's respiratory status.

- Patients with significant hypoxia (i.e.,  $\text{PaO}_2 < 60$  mm Hg [8.6 kPa] or  $\text{SaO}_2 < 90\%$ ) on room air may require intubation and ventilation within the first hour after injury. Associated medical conditions, such as chronic obstructive pulmonary disease and renal failure, increase the likelihood of requiring early intubation and mechanical ventilation.

A flail chest is defined as fractures of 2 or more contiguous ribs in 2 or more locations. This results in a segment of the chest wall (the 'flail') that is no longer in continuity with the rest of the thoracic cage.

Paradoxical movement results, the segment moves inwards on inspiration as the rest of the chest expands and outwards on expiration as the rest of the chest deflates.

Rib fractures on opposite sides of the chest can result in a 'central flail' involving the sternum.

#### Recognition

- Chest pain
- Respiratory distress
- Bony crepitus
- Paradoxical chest wall movements of the affected segment (not apparent if positive pressure ventilation applied)

#### Management

- High flow oxygen to maintain SpO<sub>2</sub> target (e.g. 15L/min via non-rebreather mask)
  - Early use of regional anesthesia (e.g. intercostal nerve blocks, paravertebral block, epidural anesthesia) due to risk of respiratory depression
- Respiratory monitoring and support
  - close monitoring of SaO<sub>2</sub>, respiratory effort, and ABGs is important as patients tend to gradually deteriorate and may require intubation and mechanical ventilation
  - may benefit from non-invasive ventilation
- Surgical intervention
  - selected patients may benefit from rib fixation (e.g. failure of analgesia and non-surgical interventions prior to intubation, or failure to wean from mechanical ventilation)

Definitive treatment of flail chest and pulmonary contusion involves ensuring adequate oxygenation, administering fluids judiciously, and providing analgesia to improve ventilation. The plan for definitive management may change with time and patient response, warranting careful monitoring and reevaluation of the patient.

Analgesia can be achieved with intravenous narcotics or local anesthetic administration, which avoids the potential respiratory depression common with systemic narcotics. Options for administering local anesthetics include intermittent intercostal nerve block(s) and transcutaneous intrapleural, extrapleural, or epidural anesthesia. When used properly, local anesthetic agents can provide excellent analgesia and prevent the need for intubation. However, prevention of hypoxia is of paramount importance for trauma patients, and a short period of intubation and ventilation may be necessary until clinicians have diagnosed the entire injury pattern. Careful assessment of the patient's respiratory rate, arterial oxygen saturation, and work of breathing

### **PULMONARY CONTUSION AND OTHER INJURIES**

- Pulmonary contusion can occur with any significant thoracic injury.
- Lung hemorrhage and pulmonary edema leads to impaired gas exchange and respiratory insufficiency.
- Lesions may progress over hours to days (e.g. peak at 72 hours then resolve over 7 days) then gradually improve.

#### Recognition

- Suspect in any significant thoracic trauma
- May occur in small children in the absence of fractures due to the high compliance of the chest wall
- Respiratory distress, hemoptysis, cyanosis
- Decreased breath sounds and crackles in the affected lung area
- Hypoxia and/ or hypercapnia on ABG
- Pulmonary contusions are detectable on bedside ultrasound
- Alveolar opacities on CXR
- MAY be complicated by nosocomial pneumonia

#### Management

High flow oxygen 15 L/min via non-rebreather mask

- ‘Fluid restriction’ may reduce size of contusion but may not affect outcomes
- Analgesia for pain from associated thoracic injuries, which may impair respiratory function
- Respiratory support — severe cases require intubation and mechanical ventilation
- Pulmonary lacerations may be managed conservatively with an intercostal catheter, thoracotomy and lung repair may be required

#### Blunt Cardiac Injury

Recent literature review demonstrates 50% of blunt cardiac injury (BCI) was related to motor vehicle crash (MVC), followed by pedestrian struck by vehicles, motorcycle crashes, and then falls from heights greater than 20 feet (6 meters). Blunt cardiac injury can result in myocardial muscle contusion, cardiac chamber rupture, coronary artery dissection and/or thrombosis, and valvular disruption. Cardiac rupture typically presents with cardiac tamponade and should be recognized during the primary survey. However, occasionally the signs and symptoms of tamponade are slow to develop with an atrial rupture. Early use of FAST can facilitate diagnosis.

Trauma team members must consider the importance of BCI due to trauma. Patients with blunt myocardial injury may report chest discomfort, but this symptom is often attributed to chest wall contusion or fractures of the sternum and/or ribs. The true diagnosis of blunt myocardial injury can be established only by direct inspection of the injured myocardium. Clinically significant sequelae are hypotension, dysrhythmias, and/or wall-motion abnormality on two-dimensional echocardiography. The electrocardiographic changes are variable and may even indicate frank myocardial infarction. Multiple premature ventricular contractions, unexplained sinus tachycardia, atrial fibrillation, bundle-branch block (usually right), and ST segment changes are the most common ECG findings. Elevated central venous pressure with no obvious cause may indicate right ventricular dysfunction secondary to contusion. Clinicians must also remember that the traumatic event may have been precipitated by a myocardial ischemic episode.

- spectrum of injury from minor enzyme rises to fulminant cardiac failure and lethal cardiac rupture

#### Recognition

- Suspect if severe blunt trauma with fractures of the sternum, ribs and/ or thoracic vertebrae
- Chest pain
- Persistent unexplained tachycardia
- pericardial injury: can produce herniation and cardiac dysfunction
- valvular: aortic > mitral > tricuspid + pulmonary valves; results in murmurs and heart failure
- septal injury: loud holosystolic murmur
- Suspect cardiac contusion if any underlying ECG abnormality, including any arrhythmia, conduction defect or ischaemic changes such as ST segment deflections and T wave changes

- Troponin doesn't alter management

#### Management

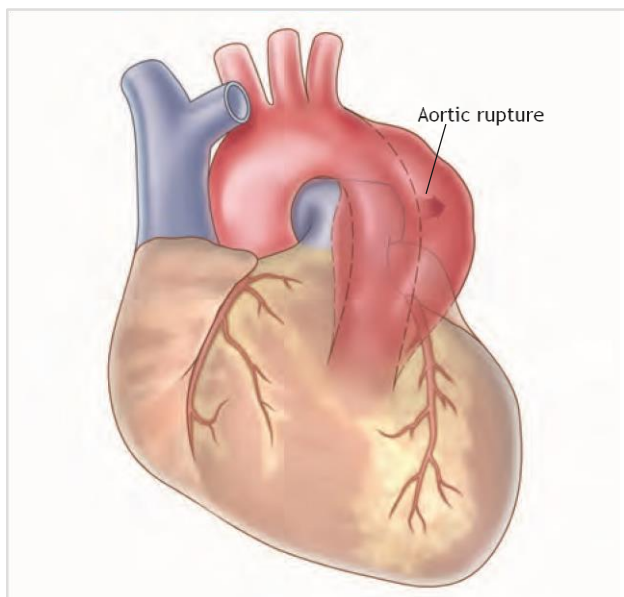
- Cardiology consult and admission for cardiac monitoring and echocardiogram
- medical management/PCI/stent/ CABG for coronary artery injury
- cardiac surgery may be required for valvular dysfunction and penetrating injuries  
emergency thoracotomy may be required in the event of a cardiac arrest

The presence of cardiac troponins can be diagnostic of myocardial infarction. However, their use in diagnosing blunt cardiac injury is inconclusive and offers no additional information beyond that available from ECG. Patients with a blunt injury to the heart diagnosed by conduction abnormalities (an abnormal ECG) are at risk for sudden dysrhythmias and should be monitored for the first 24 hours. After this interval, the risk of a dysrhythmia appears to decrease substantially. Patients without ECG abnormalities do not require further monitoring.

### Traumatic Aortic Disruption

Traumatic aortic rupture is a common cause of sudden death after a vehicle collision or fall from a great height. Survivors of these injuries frequently recover if aortic rupture is promptly identified and treated expeditiously. Those patients with the best possibility of surviving tend to have an incomplete laceration near the ligamentum arteriosum of the aorta. Continuity is maintained by an intact adventitial layer or contained mediastinal hematoma, preventing immediate exsanguination and death ( FIGURE 10).

Blood may escape into the mediastinum, but one characteristic shared by all survivors is that they have a contained hematoma. Persistent or recurrent hypotension is usually due to a separate, unidentified bleeding site. Although free rupture of a transected aorta into the left chest does occur and can cause hypotension, it usually is fatal unless the trauma team can repair it within a few minutes.



**FIGURE 10 Aortic Rupture.** Traumatic aortic rupture is a common cause of sudden death after a vehicle collision or fall from a great height. Maintain a high index of suspicion prompted by a history of decelerating force and characteristic findings on chest x-ray films.

- Aortic disruption in trauma typically involves a tear on the aortic wall due to acceleration-deceleration forces
- May result from penetrating (usually succumb in the field) or blunt injury
- Those that make it to hospital may only have the outer aortic wall layer, the adventitia, intact containing a hematoma

#### Recognition

- Conscious patients may experience tearing chest and back pain. Neurological deficits may also be present (e.g. dissection involvement origins of carotid arteries, spinal arteries, etc)
- Clinical signs (such as differences in blood pressure and pulses between the upper limbs) are unreliable.
- Suspect based on mechanism and the presence of other injuries (e.g. fractures of the sternum, upper ribs and scapula)
- Look for features of aortic dissection on CXR (especially widened mediastinum) — though these are often absent
- Essential to have a low threshold for definitive test: CT angiogram of the aorta
- Pericardial tamponade or an aortic dissection flap may be seen on echocardiography (TOE is more sensitive than TTE)

#### Management

- High flow oxygen 15L/min via non-rebreather mask
- Avoid excessive fluid resuscitation
- Lower the pulse rate to decrease aortic shear forces by commencing beta blockade (e.g. titrated esmolol infusion) then commence GTN infusion to aiming for systolic blood pressure of 90-100 mmHg and adequate tissue perfusion
- Definitive treatment is surgery, stenting or both

Specific signs and symptoms of traumatic aortic disruption are frequently absent. Maintain a high index of suspicion prompted by a history of decelerating force and its characteristic findings on chest x-ray, and evaluate the patient further. Other radiographic signs of blunt aortic injury include:

- Widened mediastinum
- Obliteration of the aortic knob
- Deviation of the trachea to the right
- Depression of the left mainstem bronchus
- Elevation of the right mainstem bronchus
- Obliteration of the space between the pulmonary artery and the aorta (obscuration of the aortopulmonary window)
- Deviation of the esophagus (nasogastric tube) to the right
- Widened paratracheal stripe
- Widened paraspinal interfaces
- Presence of a pleural or apical cap
- Left hemothorax
- Fractures of the first or second rib or scapula

Helical contrast-enhanced computed tomography (CT) of the chest has proven to be an accurate screening method for patients with suspected blunt aortic injury. CT scanning should be

performed liberally, because the findings on chest x-ray, especially the supine view, are unreliable. The sensitivity and specificity of helical contrast-enhanced CT have been shown to be close to 100%, but this result is technology dependent. If this test is negative for mediastinal hematoma and aortic rupture, no further diagnostic imaging of the aorta is likely necessary, although the surgical consultant will dictate the need for further imaging. Transesophageal echocardiography (TEE) appears to be a useful, less invasive diagnostic tool. The trauma surgeon caring for the patient is in the best position to determine which, if any, other diagnostic tests are warranted.

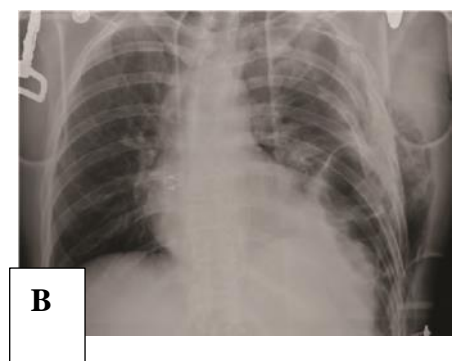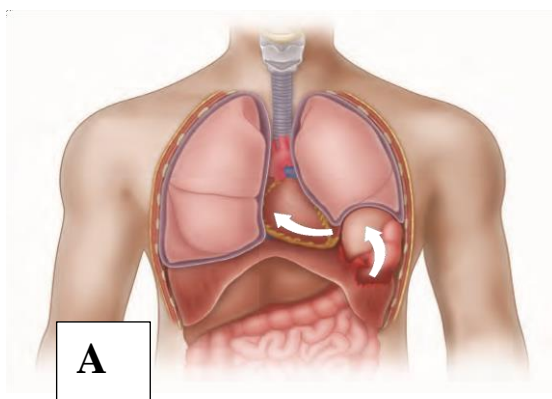
Heart rate and blood pressure control can decrease the likelihood of rupture. Pain should first be controlled with analgesics. If no contraindications exist, heart rate control with a short-acting beta blocker to a goal heart rate of less than 80 beats per minute (BPM) and blood pressure control with a goal mean arterial pressure of 60 to 70 mm Hg is recommended. When beta blockade with esmolol is not sufficient or contraindicated, a calcium channel blocker (nicardipine) can be used; if that fails, nitroglycerin or nitroprusside can be carefully added. Hypotension is an obvious contraindication to these medications.

A qualified surgeon should treat patients with blunt traumatic aortic injury and assist in the diagnosis. Open repair involves resection and repair of the torn segment or, infrequently, primary repair. Endovascular repair is the most common option for managing aortic injury and has excellent short-term outcomes.

### **Traumatic Diaphragmatic Injury**

Traumatic diaphragmatic ruptures are more commonly diagnosed on the left side, perhaps because the liver obliterates the defect or protects it on the right side, whereas the appearance of displaced bowel, stomach, and/or nasogastric (NG) tube is more easily detected in the left chest. Blunt trauma produces large radial tears that lead to herniation ( FIGURE 11), whereas penetrating trauma produces small perforations that can remain asymptomatic for years.

Diaphragmatic injuries are frequently missed initially when the chest film is misinterpreted as showing an elevated diaphragm, acute gastric dilation, loculated hemopneumothorax, or subpulmonic hematoma. Appearance of an elevated right diaphragm on a chest x-ray may be the only finding of a right-sided injury. If a laceration of the left diaphragm is suspected, a gastric tube can be inserted; if the gastric tube appears in the thoracic cavity on the chest film, the need for special contrast studies is eliminated. Occasionally, the condition is not identified on the initial x-ray film or subsequent CT scan, in which case an upper gastrointestinal contrast study should be performed. The appearance of peritoneal lavage fluid in the chest tube drainage also confirms the diagnosis in patients who have undergone diagnostic peritoneal lavage. Minimally invasive endoscopic procedures (e.g., laparoscopy and thoracoscopy) may be helpful in evaluating the diaphragm in indeterminate cases. Operation for other abdominal injuries often reveals a diaphragmatic tear. Treatment is by direct repair.



**FIGURE 11 Diaphragmatic Rupture. A.** Blunt trauma produces large radial tears that lead to herniation, whereas penetrating trauma produces small perforations that can take time—sometimes even years—to develop into diaphragmatic hernias. **B.** Radiograph view

- Diaphragmatic injuries may occur from either blunt or penetrating trauma (especially on the left side) and are easily missed.
  - Blunt injury causes radial tears that tend to allow herniation of abdominal structures into the thoracic cavity early.
  - Penetrating injuries can cause small defects that don't present with herniation until years later.
- Recognition

Suspect with any penetrating injury that could extend to between the T4 and T12 levels

- Suspect with severe blunt trauma to the torso, especially if there were compressive or rapid deceleration forces
- May be asymptomatic initially
- Abdominal pain, guarding and/or rigidity
- Cardiovascular and/or respiratory compromise may occur if abdominal contents herniate into the thoracic cavity
- Herniation may be detected by hearing bowel sounds on chest auscultation, or by CXR (NG tube tip may extend into the thoracic cavity) or bedside ultrasound
- Diagnosis of diaphragmatic rupture is usually on multidetector CT, though even a normal CT does not rule out the diagnosis
- Laparoscopy or open exploration are the gold standard for diagnosis

Management

- Laparoscopy or thoracoscopy if suspected
- Most require formal surgical repair

### **Blunt Esophageal Rupture**

Esophageal trauma most commonly results from penetrating injury. Although rare, blunt esophageal trauma, caused by the forceful expulsion of gastric contents into the esophagus from a severe blow to the upper abdomen, can be lethal if unrecognized. This forceful ejection produces a linear tear in the lower esophagus, allowing leakage into the mediastinum. The resulting mediastinitis and immediate or delayed rupture into the pleural space causes empyema.

The clinical picture of patients with blunt esophageal rupture is identical to that of post-emetic esophageal rupture. The clinical setting of esophageal injury is typically a patient with a left pneumothorax or hemothorax without a rib fracture who has received a severe blow to the lower sternum or epigastrium and is in pain or shock out of proportion to the apparent injury.

Particulate matter may drain from the chest tube after the blood begins to clear. The presence of mediastinal air also suggests the diagnosis, which often can be confirmed by contrast studies and/or esophagoscopy.

Traumatic esophageal perforation is usually caused by penetrating trauma

Recognition

- Chest or epigastric pain, dysphagia, hematemesis
- Neck and/or chest wound
- Surgical emphysema
- Pleural effusion, especially on left side (CXR or bedside ultrasound)
- Drainage of gastrointestinal contents from an intercostal catheter
- Shock (sepsis ensues if delayed presentation due to GI contents in the thoracic cavity)

## Management

- High flow oxygen 15L/min via non-rebreather mask
- Fluid resuscitation
- Nasogastric tube on free drainage
- Broad spectrum antibiotics
- Formal surgical repair

Treatment of esophageal rupture consists of wide drainage of the pleural space and mediastinum with direct repair of the injury. Repairs performed within a few hours of injury improve the patient's prognosis.

## Other Manifestations of Chest injuries

During the secondary survey, the trauma team should look for other significant thoracic injuries including subcutaneous emphysema; crushing injury (traumatic asphyxia); and rib, sternum, and scapular fractures. Although these injuries may not be immediately life-threatening, they can potentially cause significant morbidity

### Subcutaneous Emphysema

Subcutaneous emphysema can result from airway injury, lung injury, or, rarely, blast injury. Although this condition does not require treatment, clinicians must recognize the underlying injury and treat it. If positive-pressure ventilation is required, consider performing tube thoracostomy on the side of the subcutaneous emphysema in case a tension pneumothorax develops.

### Crushing Injury to the Chest

Findings associated with a crush injury to the chest, or traumatic asphyxia, include upper torso, facial, and arm plethora with petechiae secondary to acute, temporary compression of the superior vena cava. Massive swelling and even cerebral edema may be present. Associated injuries must be treated.

### Rib, Sternum, and Scapular Fractures

The ribs are the most commonly injured component of the thoracic cage, and injuries to the ribs are often significant. Pain on motion typically results in splinting of the thorax, which impairs ventilation, oxygenation, and effective coughing. The incidence of atelectasis and pneumonia rises significantly with preexisting lung disease.

The scapula, humerus, and clavicle, along with their muscular attachments, provide a barrier to injury to the upper ribs (1 to 3). Fractures of the scapula, first or second rib, or the sternum suggest a magnitude of injury that places the head, neck, spinal cord, lungs, and great vessels at risk for serious associated injury. Due to the severity of the associated injuries, mortality can be as high as 35%.

Sternal and scapular fractures generally result from a direct blow. Pulmonary contusion may accompany sternal fractures, and blunt cardiac injury should be considered with all such fractures. Operative repair of sternal and scapular fractures occasionally is indicated. Rarely, posterior

sternoclavicular dislocation results in mediastinal displacement of the clavicular heads with accompanying superior vena caval obstruction. Immediate reduction is required.

The middle ribs (4 to 9) sustain most of the effects of blunt trauma. Anteroposterior compression of the thoracic cage will bow the ribs outward and cause midshaft fractures. Direct force applied to the ribs tends to fracture them and drive the ends of the bones into the thorax, increasing the potential for intrathoracic injury, such as a pneumothorax or hemothorax.

In general, a young patient with a more flexible chest wall is less likely to sustain rib fractures. Therefore, the presence of multiple rib fractures in young patients implies a greater transfer of force than in older patients.

The presence of rib fractures in the elderly should raise significant concern, as the incidence of pneumonia and mortality is double that in younger patients.

Fractures of the lower ribs (10 to 12) should increase suspicion for hepatosplenic injury. Localized pain, tenderness on palpation, and crepitation are present in patients with rib injury. A palpable or visible deformity suggests rib fractures. In these patients, obtain a chest x-ray primarily to exclude other intrathoracic injuries and not simply to identify rib fractures. Fractures of anterior cartilages or separation of costochondral junctions have the same significance as rib fractures, but they are not visible on the x-ray examinations. Special techniques for rib x-rays are not considered useful, because they may not detect all rib injuries and do not aid treatment decisions; further, they are expensive and require painful positioning of the patient. Taping, rib belts, and external splints are contraindicated. Relief of pain is important to enable adequate ventilation. Intercostal block, epidural anesthesia, and systemic analgesics are effective and may be necessary. Early and aggressive pain control, including the use of systemic narcotics and topical, local or regional anesthesia, improves outcome in patients with rib, sternum, or scapular fractures.

Increased use of CT has resulted in the identification of injuries not previously known or diagnosed, such as minimal aortic injuries and occult or subclinical pneumothoraces and hemothoraces. Clinicians should discuss appropriate treatment of these occult injuries with the proper specialty consultant.

## **Conclusion**

1. Thoracic injury is common in the polytrauma patient and can pose life-threatening problems if not promptly identified and treated during the primary survey. These patients can usually be treated or their conditions temporarily relieved by relatively simple measures, such as intubation, ventilation, tube thoracostomy, and fluid resuscitation. Clinicians with the ability to recognize these important injuries and the skill to perform the necessary procedures can save lives. The primary survey includes management of airway obstruction, laryngeal injury, upper chest injury, tracheobronchial tree injury, tension pneumothorax, open pneumothorax, massive hemothorax, cardiac tamponade, and traumatic circulatory arrest.
2. The secondary survey includes identification, using adjunctive studies such as x-rays, laboratory tests, and ECG, and initial treatment of the following potentially life-threatening injuries: simple pneumothorax, hemothorax, pulmonary contusion, flail chest, blunt cardiac injury, traumatic aortic disruption, traumatic diaphragmatic injury, and blunt esophageal rupture.



3. Several manifestations of thoracic trauma may indicate a greater risk of associated injuries, including subcutaneous emphysema, crush injuries of the chest, and injuries to the ribs, scapula, and sternum.

## **Bibliography**

1. Roberts D, Leigh-Smith S, Faris P, et al. Clinical presentation of patients with tension pneumothorax: a systematic review. *Ann Surg* 2015;261(6):1068–1078.
2. Advanced Trauma Life Support ATLS American College of Surgeons. Student Course Manual 2018.