

# BASIC LIFE SUPPORT

State University of Medicine and Pharmacy “Nicolae Testemitanu”,  
Gh. Ciobanu,

Head of the Department of Emergency Medicine, PhD, professor

## OBJECTIVES

INTRODUCTION

ADULT CHAIN OF SURVIVAL

THE SYSTEMATIC APPROACH

BASIC LIFE SUPPORT

A. AIRWAY

B. BREATHING

C. CIRCULATION

FOREIGN BODY AIRWAY OBSTRUCTION MANAGEMENT

AUTOMATED EXTERNAL DEFIBRILLATOR FOR ADULT

CONCLUSIONS

BIBLIOGRAPHY

## Definitions

- Basic Life Support (BLS). - BLS is the phase of ECC that includes recognition of cardiac arrest, access to the EMS system, and basic CPR.
- Basic CPR. - Basic CPR is the attempt to restore spontaneous circulation using the techniques of chest wall compressions and pulmonary ventilation.

BLS consists of four steps:

Step A: airway control

Step B: breathing support, emergency artificial ventilation and oxygenation of the lung

Step C: circulation support, recognition of pulselessness and establishment of artificial circulation by cardiac compressions, control of hemorrhage and positioning for shock

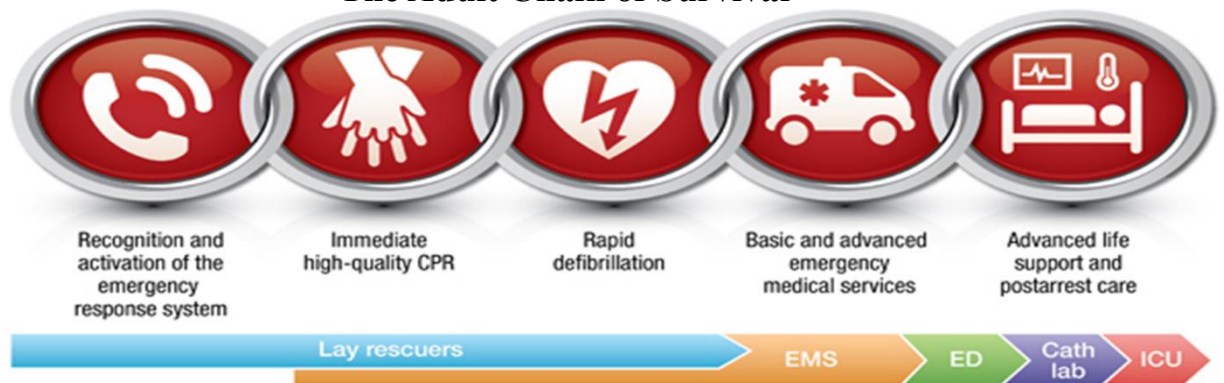
Step D - Defibrillation: Automated External Defibrillators.

Sudden Cardiac Arrest (Cardiac arrest) is clinically diagnosed when the following four conditions coexist:

1. Unconsciousness
2. Apnea or gasping respiration
3. Pulselessness in large arteries (carotid)
4. Death-like appearance

Successful resuscitation following cardiac arrest requires an integrated set of coordinated actions represented by the links in the adult Chain of Survival.

## The Adult Chain of Survival



The links include the following:

- **Immediate recognition of cardiac arrest and activation of the emergency response system**
- **Immediate high-quality CPR**
- **Rapid defibrillation**
- **Basic and advanced emergency medical services**
- **Advanced life support and postarrest care**

#### **Risks to EMS personnel:**

All body fluids, not just blood, are potentially infectious

#### *Protective equipment:*

- Medical Gloves are considered standard protective equipment for all patient contacts
- Protective glasses
- Surgical mask
- Gown

High-visibility clothing

Before approaching collapsed patient EMS personnel should rapidly assess any personal danger such as falling masonry, gas, electricity, fire, or traffic.

Disease transmission

- Tuberculosis (TB)
- Severe Acute Respiratory Distress Syndrome (SARS)
- Hepatitis B virus or meningococcal meningitis

#### **Transmission of HIV during CPR has never been reported**

#### **ABCD – Primary Survey**

In the primary survey, focus on basic CPR and defibrillation First „A-B-C-D”

A - Airway: open the airway

B – Breathing: provide positive pressure ventilation

C - Circulation: give chest compressions

D - Defibrillation: shock VF/pulseless VT

#### **2011-2015-2020**

C – Circulation. CPR in cardiac arrest should start with chest compression

A – Airway

B – Breathing

### **Anatomy of the Respiratory System**

The airway is composed of the following elements:

#### A. Upper Airway

- Nose and mouth
- Pharynx (behind the tongue)
- Nasopharynx
- Oropharynx
- Larynx or voice box

#### B. Lower Airway

- Trachea or windpipe;
- Bronchi - the right and the left primary bronchi;

- The point where the trachea divide into the right and left primary bronchi called the carina;
- The right primary bronchus is straighter or less angled than the left. Foreign bodies tend to make their way into the right primary bronchus more often;
- Bronchioles, branches of the bronchi that terminate in the alveoli; Alveoli.

### **Upper Airway Obstruction**

- Trauma to face and throat
- Unconscious – posterior displacement of the tongue caused by decreased muscle tone
- Foreign body (e.g. tooth, food)
- Laryngeal spasm and oedema
- Epiglottitis
- Pharyngeal swelling (e.g. infection, oedema)

### **Lower Airway Obstruction**

- Central nervous system depression
  - Bronchospasm-causes narrowing of the small airways in the lung
  - Blocked tracheostomy
  - Foreign body
- Tracheobronchial aspiration of:
- Blood
  - Vomitus
  - Bronchial secretions
  - Anaphylaxis

### **Airway Management Procedure**

1. Triple Airway Maneuver Safar
  - Head Tilt
  - Jaw Thrust
  - Mouth open
2. Head Tilt-Chin Lift
3. Jaw Thrust
  - Jaw Thrust without Head Tilt
  - Jaw Thrust with Head Tilt
4. Remove a visible foreign body by used Magill or Kocher forceps.
5. Insertions an oropharyngeal airway (oropharyngeal tubes Guedel or Berman types, S-tubes Safar)
6. Insertion an nasopharyngeal airway (Robertazzy tubes)
7. Insertion an Esophageal Obturator Airway
8. Insertion an Laryngeal Mask Airway.

#### **1. Triple Airway Maneuver Safar**

- **Head tilt**
- **Jaw Thrust (Esmarch-Heiberg)**
- **Mouth open**
- Back ward tilt of the head.
- Grasp the ascending rami of patients mandible in front of his ear lobes using fingers 2-5 of both hands and pull forwards, displacing the mandible so that the lower teeth just out in front of the upper teeth.

- With your thumbs open the mouth.

**The triple airway maneuver Safar is a technique for opening the airway of an unresponsive patient without suspected cervical spine injury.**

## 2. Head Tilt-Chin Lift Maneuver

Action
Place one hand on the victim's forehead and push with your palm to tilt the head back.
Place the fingers of the other hand under the bony part of the lower jaw near the chin.
Lift the jaw to bring the chin forward.

## 3. Jaw Thrust Maneuver

Jaw Thrust

- Jaw thrust without head tilt
- Jaw thrust with head tilt

### Jaw Thrust Without Head Tilt

- The Jaw thrust without head tilt maneuver is the technique that is recommended for opening the airway when cervical spine injury is suspected.
- Ensure that the patient is in a supine position while stabilizing the patient's head in a neutral position, grasp the angles of the patient lower jaw with your finger tips.
- Displace the lower jaw forward.

## 4. Remove a visible foreign body with Magill or Kocher forceps

**5. Airway Adjuncts** Airway adjuncts prevent the tongue from falling back into the airway and blocking the flow of air.

### Oral airways

- Oral airway's is also called an oropharyngeal airway (OPA) Indications for insertion include patients who are unresponsive and have no gag reflex.
- An OPA is a J-shaped plastic or rubber device that is used to create an air passage between the patient's mouth and the posterior wall of the pharynx when correctly positioned the flange of the device rests on the patient's lips or teeth.
- The distal tip lies between the base of the tongue and the back of the throat preventing the tongue from blocking the airway.
- Air passes around and through the device .
- Oral airway is available in a variety of sizes that range from 0 for neonates up to 6 for large adults.

### S-tubes Safar

- S-shaped mouth-to-mouth airways
- Insert like regular oropharyngeal tubes

## 6. Nasopharyngeal Airway

Nasopharyngeal Airway size is determined by holding the device against the side of the patient face and selecting an airway that extends from the tip of the nose to the angle of the jaw or the tip of the ear.

- Contraindications- Severe craniofacial trauma;
- Patient intolerance.

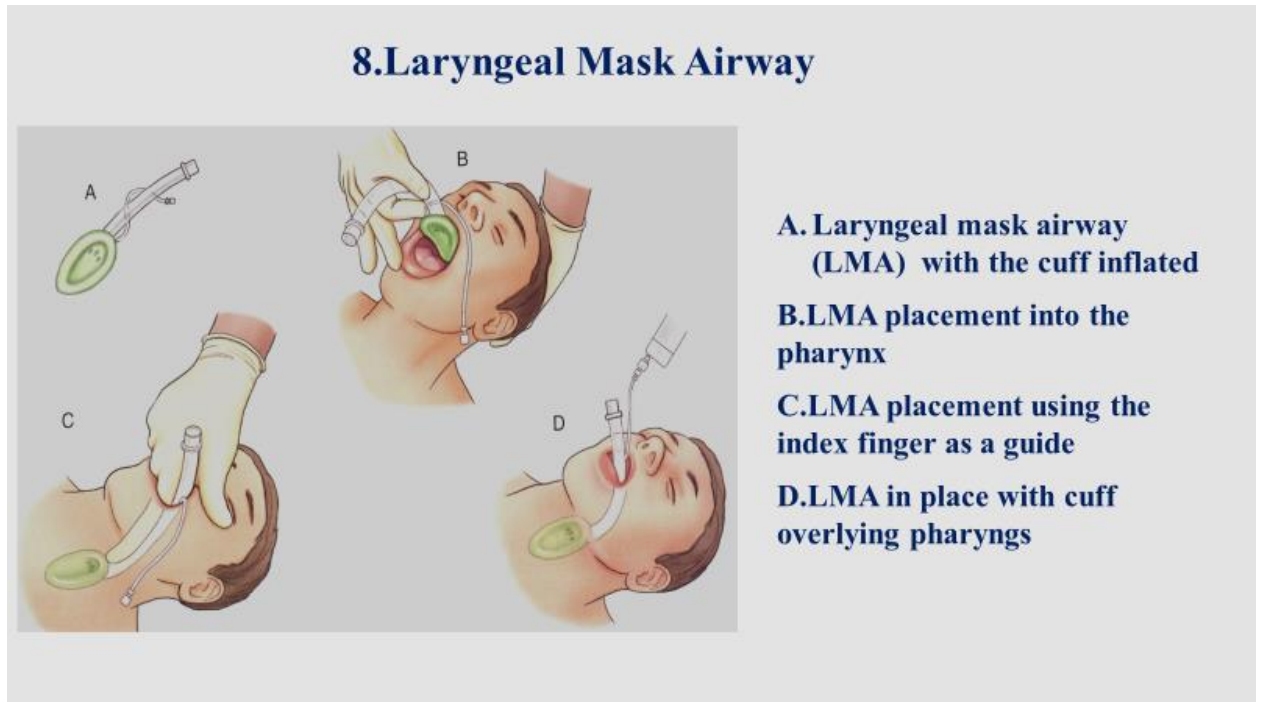
**7. Esophageal Obturator Airway (EOA)** Esophageal Obturator Airway is used to prevent gastric regurgitation and gastric insufflation during artificial ventilation. EOA is large tube a rounded closed tip distally a cuff to be inflated in the esophagus and multiple opening at the hypopharyngeal level through which air or oxygen is delivered into the larynx and trachea.

- For insertion only into relaxed apneic adult patient by person unable to perform tracheal intubation.

- Blind insertion via mouth into esophagus
- For insertion keep neck slightly flexed

### 8.Laryngeal Mask Airway

- An LMA is a device that functions intermediately between an OPA and a tracheal tube and does not require direct visualization of the airway for insertion.
- The LMA is available in sizes for neonates, infants, young children, older children, and small average, and large adults. The LMA consists of a tube fitted with an oval mask and an inflatable rim.



### B-Breathing Providing Basic Ventilation

- Mouth-to-mouth ventilation
- Mouth-to-nose ventilation
- Mouth-to-barrier device ventilation
- Mouth-to-pocket mask ventilation
- Bag-mask ventilation

#### Check for Breathing Look for the chest to rise and fall

Listen for air escaping during exhalation

Fell for flow of air against your cheek

The evaluation procedure should take at least 5 seconds but no more than 10 seconds

#### Mouth-to-Mouth Breathing.

Mouth-to-mouth breathing is a quick, effective way to provide oxygen to the victim. The rescuer's exhaled air contains approximately 17% oxygen and 4% carbon dioxide. This is enough oxygen to supply the victim's needs.

Follow these steps to give mouth-to-mouth breaths to the victim:

<b>Action</b>
<b>Hold the victim's airway open with a head tilt-chin lift.</b>
<b>Pinch the nose closed with your thumb and index finger (using the hand on the forehead).</b>
<b>Take a regular (not deep) breath and seal your lips around the victim's mouth, creating an airtight seal.</b>
<b>Give 1 breath (blow for 1 second). Watch for the chest to rise as you give the breath.</b>
<b>If the chest does not rise, repeat the head tilt-chin lift.</b>
<b>Give a second breath (blow for 1 second). Watch for the chest to rise.</b>

### **Mouth – to – Nose Breathing**

Mouth – to – nose ventilation is an effective alternative to mouth – to – mouth ventilation

- If the victim's mouth is seriously injured or cannot be open (trismus)
- The rescuer is assisting a victim in the water
- A mouth – to – mouth seal is difficult to achieve

### **Mouth-to-Barrier Device Ventilation**

A barrier device is a thin film of material, usually plastic or silicone, that is placed on the patient's face and used to prevent direct contact with the patient's mouth during positive pressure ventilation. One common type of barrier device is a face shield.

- Step 1.

Put on appropriate personal protective equipment. Open the patient's airway and place the barrier device over the patient's mouth.

- Step 2.

Place your mouth over the mouthpiece of the barrier device. Take a normal breath and breathe into the device with enough force to cause the patient's chest to rise gently.

### ***Mouth-to-Mask Ventilation***

<b>Action</b>
<b>Position yourself at the victim's side.</b>
<b>Place the mask on the victim's face, using the bridge of the nose as a guide for correct position.</b>
<b>Seal the mask against the face:</b> <ul style="list-style-type: none"> <li>• <b>Using your hand that is closer to the top of the victim's head, place the index finger and thumb along the border of the mask.</b></li> <li>• <b>Place the thumb of your other hand along the lower margin of the mask.</b></li> </ul>
<b>Place the remaining fingers of your hand closer to the victim's neck along the bony margin of the jaw and lift the jaw. Perform a head tilt-chin lift to open the airway .</b>
<b>While you lift the jaw, press firmly and completely around the outside margin of the mask to seal the mask against the face.</b>
<b>Deliver air over 1 second to make the victim's chest rise.</b>

## Bag-Mask Ventilation

- A bag-mask device consists of a self-inflating bag; a non-rebreathing valve with an adapter than can be attached to a mask, a tracheal tube, or another invasive airway device; and an oxygen inlet valve.

## C-Circulation

- Check carotid puls
- External cardiac compressions

### Check Carotid Puls

Action
Maintain a head tilt with one hand on the victim's forehead.
Locate the trachea, using 2 or 3 fingers of the other hand
Slide these 2 or 3 fingers into the groove between the trachea and the muscles at the side of the neck, where you can feel the carotid pulse
Palpate the artery for at least 5 seconds and no more than 10 seconds.

## External Cardiac Compressions

- Compression of chest between sternum and spine with heel of hand applied to the sternum. Second hand applied on the top of the first hand.
- Release of pressure to let chest fill. Compress and release for 50 percent of each cycle. Maintain contact between hand and sternum.

The correct place for application of the hands-the lower half of the sternum.

Technique of external cardiac compressions.

- Identification of correct point for external cardiac compressions, by feeling for suprasternal notch and base of xiphoid, measuring one-half of this distance and compressing the lower half of the sternum.
- Alternative method for identifying the pressure point, i. e., feeling for the base of the xiphoid, measuring two fingers cephalad, and applying heel of hand over lower half of sternum.
- Body and hand position for external cardiac compressions. Compress straight downward, using part of body weight. Keep arms straight and hands off ribs. Inset: alternative method for performing external cardiac compressions with heel of lower hand, by locking fingers of both hands

**CHEST COMPRESSION TECHNIQUE** One important part of CPR is chest compressions, which keep blood flowing to the heart, brain, and other vital organs.

Action
<b>Position yourself at the victim's side.</b>
<b>Make sure the victim is lying on his back on a firm, flat surface. If the victim is lying face down, carefully roll him onto his back.</b>
<b>Move or remove all clothing covering the victim's chest. You need to see the skin.</b>
<b>Put the heel of one hand on the center of the victim's bare chest between the nipples</b>
<b>Put the heel of your other hand on top of the first hand.</b>
<b>Straighten your arms and position your shoulders directly over your hands.</b>
<b>Push hard and fast 100 to 120/min. Press down 2 inches (5 cm) with each compression. For each chest compression, make sure you push straight down on the victim's breastbone</b>
<b>At the end of each compression, make sure you allow the chest to recoil or re-expand completely. Full chest recoil allows more blood to refill the heart between chest compressions. Incomplete chest recoil will reduce the blood flow created by chest compressions.</b>
<b>Deliver compressions in a smooth fashion at a rate of 100 compressions per minute.</b>

Chest compressions should ideally be interrupted only for a ventilation (unless an advanced airway is placed), rhythm checks, and actual shock delivery. Perform a pulse check if an organized rhythm is observed.

Each time you stop chest compressions, the blood flow to the heart and brain decreases significantly. Once you resume compressions, it takes several compressions to increase blood flow to the heart and brain. Thus, the more often chest compressions are interrupted and the longer the interruptions are, the lower the blood supply to the heart and brain is.

### Physiologic Monitoring During CPR

#### End-Tidal CO<sub>2</sub>

- The main determinant of ETCO<sub>2</sub> during CPR is blood delivery to the lungs. Persistently low ETCO<sub>2</sub> values <10 mm Hg during CPR in intubated patients suggest that ROSC is unlikely. If PETCO<sub>2</sub> abruptly increases to a normal value of 35 to 40 mm Hg, it is reasonable to consider this an indicator of ROSC.
- If the ETCO<sub>2</sub> is <10 mm Hg during CPR, it is reasonable to try to improve chest compressions and vasopressor therapy.

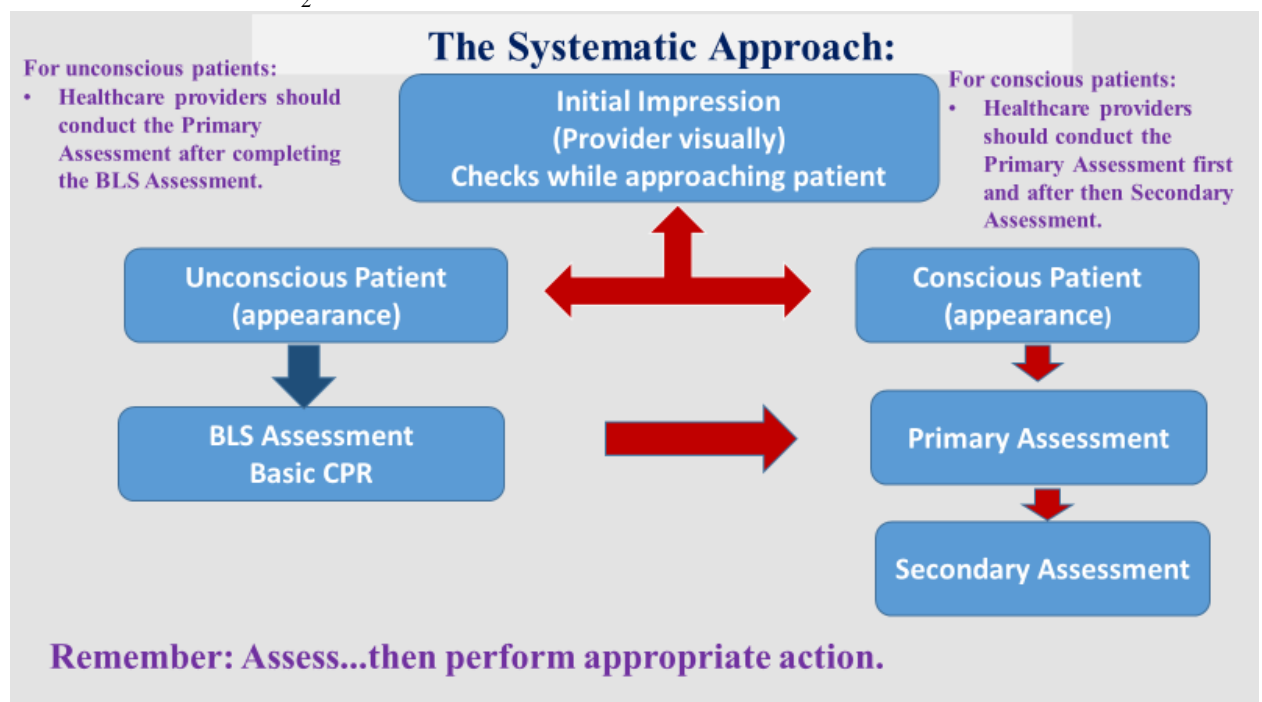
#### Coronary Perfusion Pressure or Arterial Relaxation Pressure

- Increased CPP correlates with both myocardial blood flow and ROSC. A reasonable surrogate for CPP during CPR is arterial relaxation ("diastolic") pressure, which can be measured by using an intraarterial catheter.
- If the arterial relaxation pressure is <20 mm Hg, it is reasonable to try to improve chest compressions and vasopressor therapy.

#### Central Venous Oxygen Saturation

- If oxygen consumption, arterial oxygen saturation, and hemoglobin are constant, changes in ScvO<sub>2</sub> reflect changes in oxygen delivery due to changes in cardiac output. ScvO<sub>2</sub> can be measured continuously by using oximetric tipped central venous catheters placed in the superior vena cava or pulmonary artery. Normal range is 60% to 80%.

If the ScvO<sub>2</sub> is <30%, it is reasonable to try to improve chest compressions

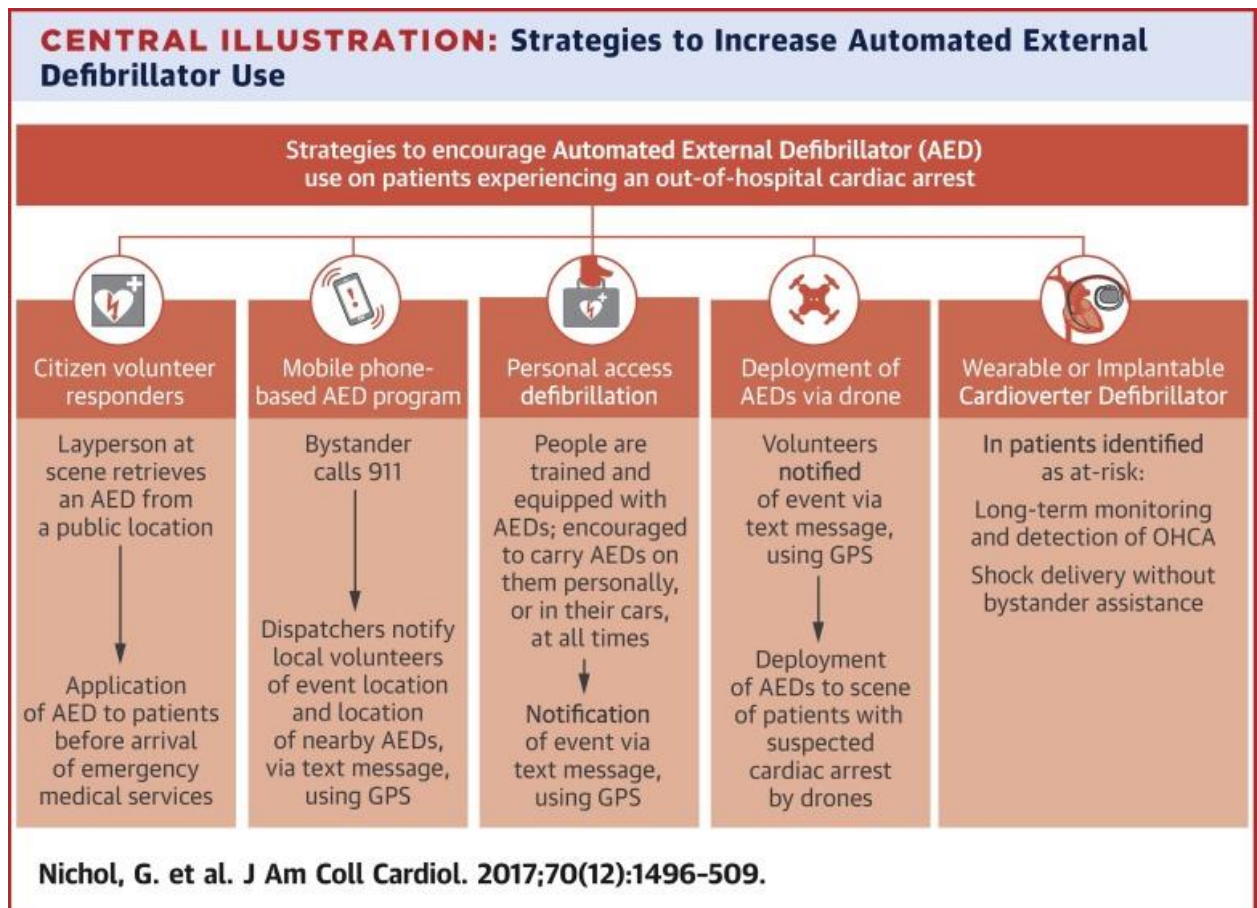




## High-Quality CPR

- Compress the chest hard and fast 100-120 per 1 min..
- Allow complete chest recoil after each compression.
- Minimize interruptions in compressions (10 seconds or less).
- Avoid excessive ventilation.
- Switch compressor about every 2 minutes or earlier if fatigued. \*

\*Switch should take 5 seconds or less.



**Agonal Gasps** are not normal breathing and may be present in the first minutes after sudden cardiac arrest.

A patient who gasps usually looks like he is drawing air in very quickly. The mouth may be open and the jaw, head, or neck may move with gasps.

Gasps may appear forceful or weak. Some time may pass between gasps because they usually happen at a slow rate.

The gasp may sound like a snort, snore, or groan. Gasping are not normal breathing. It is a sign of cardiac arrest

### Recognition of airway obstruction

Airway obstruction can be subtle and is often missed by healthcare professionals. Recognition is best achieved by the look, listen and feel approach.

- LOOK for chest and abdominal movements.
- LISTEN and FEEL for airflow at the mouth and nose.

**Partial Airway Obstruction**, air entry is diminished and usually noisy.

- Inspiratory stridor - caused by obstruction at the laryngeal level or above.
- Expiratory wheeze - suggests obstruction of the lower airways, which tend to collapse and obstruct during expiration.
- Gurgling - suggests the presence of liquid or semisolid foreign material in the upper airways.
- Snoring - arises when the pharynx is partially occluded by the tongue or palate.
- Crowing or stridor is the sound of laryngeal spasm or obstruction.

**Complete airway obstruction** in a patient who is making respiratory efforts causes paradoxical chest and abdominal movement, described as 'see-saw breathing'. As the patient attempts to breathe in, the chest is drawn in and the abdomen expands: the opposite occurs in expiration. This is in contrast to the normal breathing pattern of synchronous movement of the abdomen upwards and outwards (pushed down by the diaphragm) with lifting of the chest wall. During airway obstruction, accessory muscles of respiration are used - the neck and the shoulder muscles contract to assist movement of the thoracic cage. There may also be intercostal and subcostal recession and a tracheal tug. Full examination of the neck, chest and abdomen should enable differentiation of the movements associated with complete.

### Foreign-Body Airway Obstruction (choking)

Foreign-body airway obstruction (FBAO) is an uncommon but potentially treatable cause of accidental death.

General signs of FBAO	
<ul style="list-style-type: none"> <li>• Attack occurs while eating</li> <li>• Victim may clutch his neck</li> </ul>	
<p>Signs of mild airway obstruction</p> <p>Response to question „Are you choking?“</p> <ul style="list-style-type: none"> <li>• Victim speaks and answers yes</li> </ul> <p>Other signs:</p> <ul style="list-style-type: none"> <li>• Victim is able to speak, cough and breathe</li> </ul>	<p>Signs of sever airway obstruction</p> <p>Response to question „Are you choking?“</p> <ul style="list-style-type: none"> <li>• Victim unable to speak</li> </ul> <p>Other signs:</p> <ul style="list-style-type: none"> <li>• Victim unable to breathe</li> <li>• Breathing sounds wheezy</li> <li>• Attempts at coughing are silent</li> <li>• Victim may be unconscious</li> </ul>

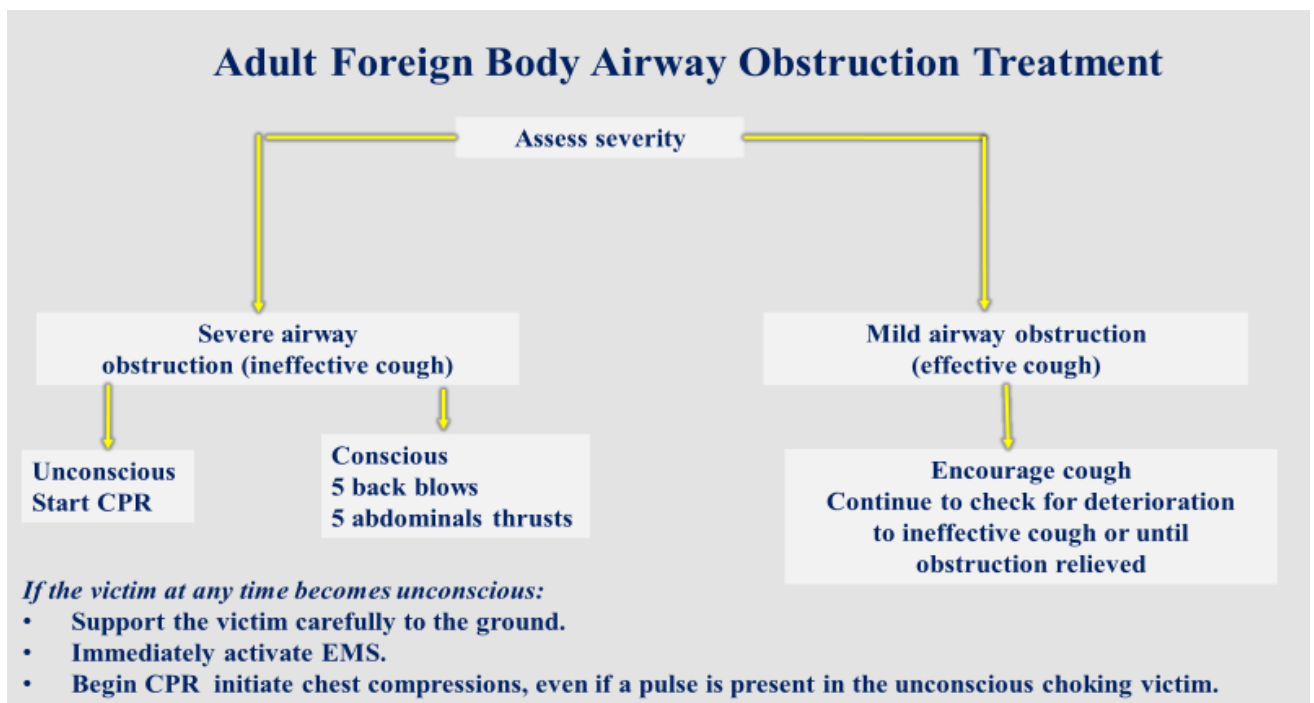
1.If the victim shows signs of mild airway obstruction:

Encourage him to continue coughing but do nothing else.

2. If the victim shows signs of severe airway obstruction:

- *If the victim is conscious:*
- Apply up to five back blows:
  - Stand to the side and slightly behind the victim.
  - Support the chest with one hand and lean the victim well forwards so that when the obstructing object is dislodged it comes out of the mouth rather than goes further down the airway.

- Give up to five sharp blows between the shoulder blades with the heel of your other hand.
- Check to see if each back blow has relieved the airway obstruction. The aim is to relieve the obstruction with each blow rather than necessarily to give all five.
- If five back blows fail to relieve the airway obstruction give up to five abdominal thrusts:
  - Stand behind the victim and put both arms round the upper part of his abdomen.
  - Lean the victim forwards.
  - Clench your fist and place it between the umbilicus and xiphisternum.
  - Grasp this hand with your other hand and pull sharply inwards and upwards.
  - Repeat up to five times.
- If the obstruction is still not relieved continue alternating five back blows with five abdominal thrusts.



### **Automated External Defibrillators**

Automated external defibrillators (AEDs) are safe and effective when used by either laypeople or healthcare professionals (in- or out-of-hospital).

Use of an AED by a layperson makes it possible to defibrillate many minutes before professional help arrives.

#### **Sequence for use of an AED**

1. Make sure you, the victim, and any EMS personnel are safe.
2. Follow the Adult BLS sequence:
  - if the victim is unresponsive and not breathing normally, send someone for help and to find and bring an AED if available;

- if you are on your own, use your mobile phone to alert the ambulance service - leave the victim only when there is no other option.

3. Start CPR according to the adult BLS sequence. If you are on your own and the AED is in your immediate vicinity, start with applying the AED.

There are 4 acceptable AED electrode pad positions:

- Anterolateral
- Anteroposterior
- Anterior-left infrascapular
- Anterior-right infrascapular

All 4 positions are equally effective in shock success and are reasonable for defibrillation.

For ease of placement, anterolateral is a reasonable default electrode placement.

4. As soon as the AED arrives:

- switch on the AED and attach the electrode pads on the victim's bare chest;
- if more than one rescuer is present, CPR should be continued while electrode pads are being attached to the chest;
- follow the spoken/visual directions immediately;
- ensure that nobody is touching the victim while the AED is analyzing

the rhythm.

5a. If a shock is indicated:

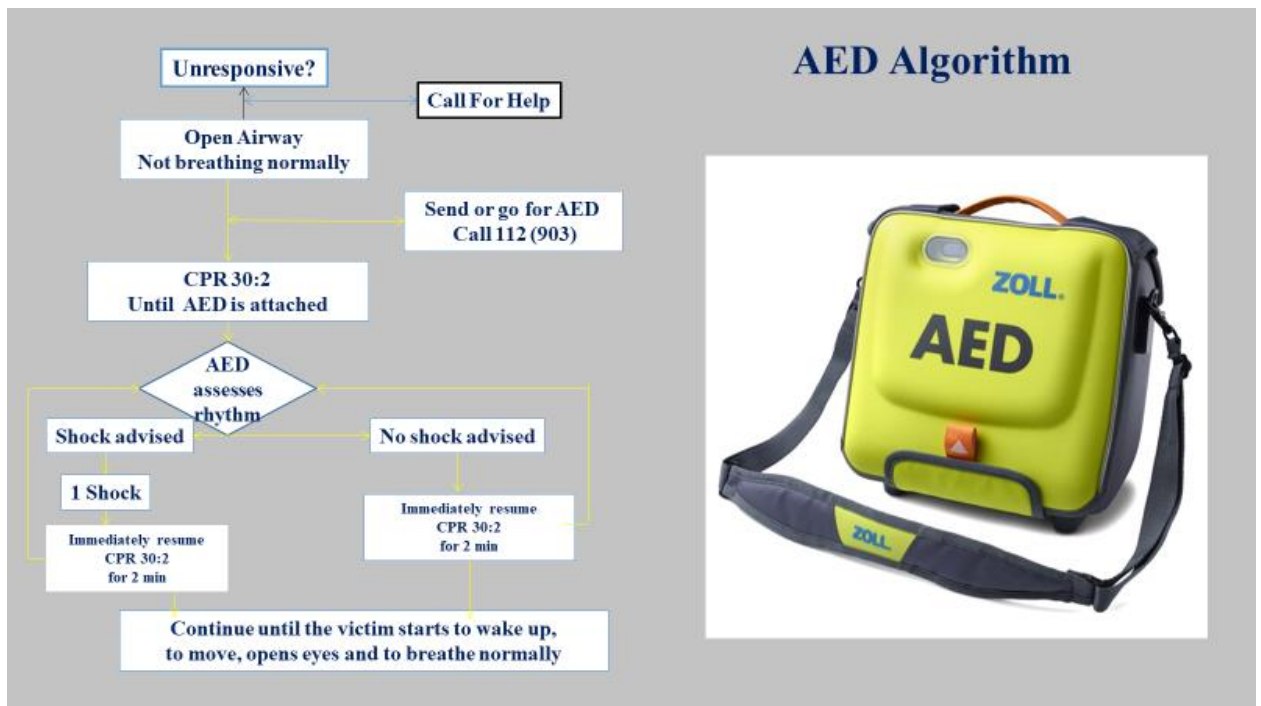
- ensure that nobody is touching the victim;
- push shock button as directed;
- immediately restart CPR 30:2;
- continue as directed by the voice/visual prompts.

5b. If no shock is indicated:

- immediately resume CPR, using a ratio of 30 compressions to 2 rescue breaths;
- continue as directed by the voice/visual prompts.

6. Continue to follow the AED prompts until:

- professional help arrives and takes over;
- the victim starts to wake up: moves, opens eyes and breathes normally;
- you become exhausted.



## CONCLUSIONS

**1.** Basic Life Support (BLS). - BLS is the phase of ECC that includes recognition of cardiac arrest, access to the EMS system, and basic CPR. .BLS consists of three steps: Step A: airway control ;Step B: breathing support, emergency artificial ventilation and oxygenation of the lung Step C: circulation support, recognition of pulselessness and establishment of artificial circulation by cardiac compressions, control of hemorrhage and positioning for shock. The links the Adult Chain of Survival include the following:

- Immediate recognition of cardiac arrest and activation of the emergency response system
- Immediate high-quality CPR
- Rapid defibrillation
- Basic and advanced emergency medical services
- Advanced life support and postarrest care

2. The critical characteristics of high-quality CPR include:

- Start compressions within 10 seconds of recognition of cardiac arrest.
- Push hard, push fast: Compress at rate of at least 100/min. with a depth of at least 2 inches (5 cm) for adults.
- Allow complete chest recoil after each compression.
- Minimize interruptions in compressions (try to limit interruptions to <10 seconds).
- Give effective breaths that make the chest rise.
- Avoid excessive ventilation.

3. An automated external defibrillator is used in cases of life-threatening cardiac arrhythmias which lead to sudden cardiac arrest The rhythms that the device will treat are usually limited to:"

Pulseless Ventricular tachycardia (shortened to VT or V-Tach)

Ventricular fibrillation (shortened to VF or V-Fib).

## REFERENCES

American Heart Association. BLS for Healthcare Providers 2016

European Resuscitation Council Guidelines for Resuscitation 2015,section 2  
Gh.Ciobanu Resuscitarea Cardiorespiratorie și Cerebrală,2015, Vol.1-2